



# Cased Based Review of Imaging for Penile Pain

Lauren Alexander, MD; Gary Padilla-Maldonado, MD;  
JD LeGout, MD; Joseph Cernigliaro, MD FSAR FACR

Department of Radiology  
Mayo Clinic  
Jacksonville, Florida

SAR 2024



SocAbdRadiology



SocietyOfAbdominalRadiology



abdominalradiology.org



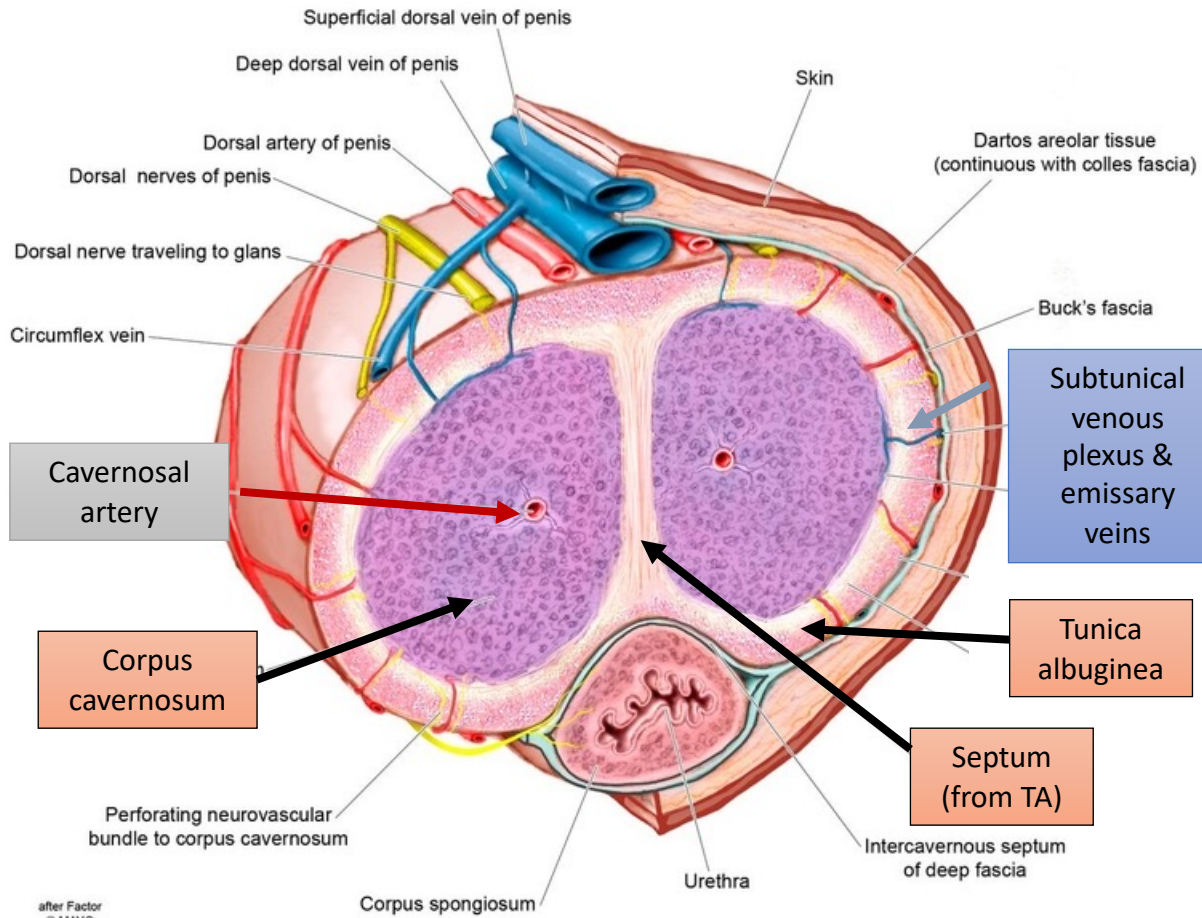
# Learning objectives

- Recognize when to use ultrasound (US), computed tomography (CT) and magnetic resonance imaging (MRI) for evaluation of penile pain.
- Identify normal penile anatomy on imaging studies.
- Describe imaging features of painful penile pathology including traumatic injuries, inflammatory disorders, and vascular disorders.
- Recognize normal and abnormal imaging findings of penile implants.

**Author disclosures:** We do not have any relationships to report with ACCME defined ineligible companies. We do not be discussing unlabeled/investigational uses of medical devices or pharmaceuticals during this presentation.

# PENILE ANATOMY

Mid-shaft Cross-section of Penis

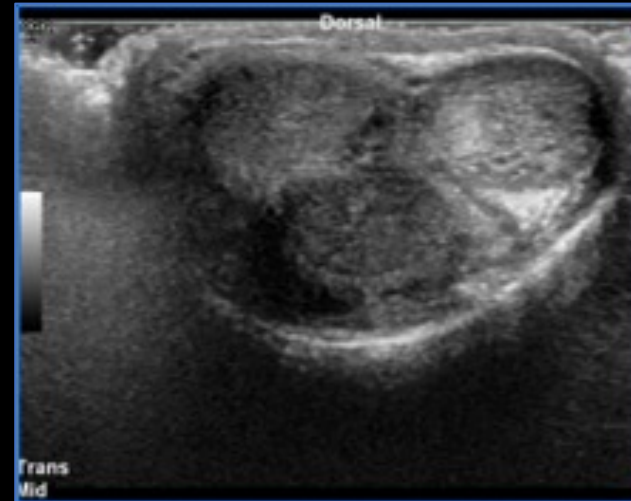


- **Corpora cavernosa (CC)**
  - Erectile tissue composed of expansile vascular sinusoids
  - Surrounded by **tunica albuginea (TA)** with fenestrations in septum
- Penile arterial supply originates from the internal iliac artery via the internal pudendal artery
  - Many arterial variants and collaterals
- CC venous drainage via subcutaneous venous plexus & emissary veins

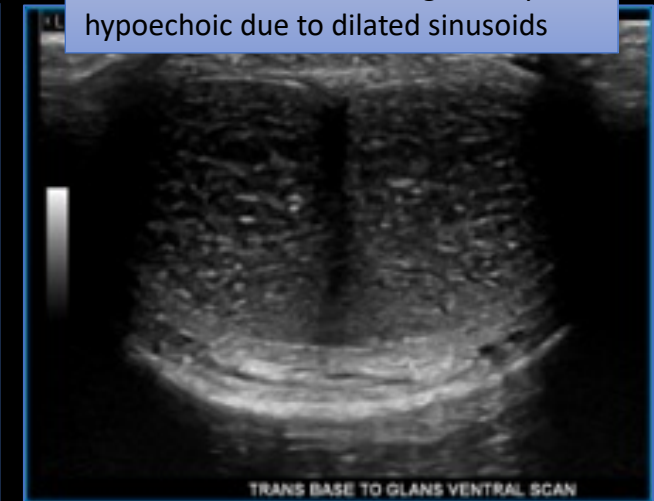
Used with permission of Mayo Foundation for Medical Education and Research, all rights reserved.

# ULTRASOUND

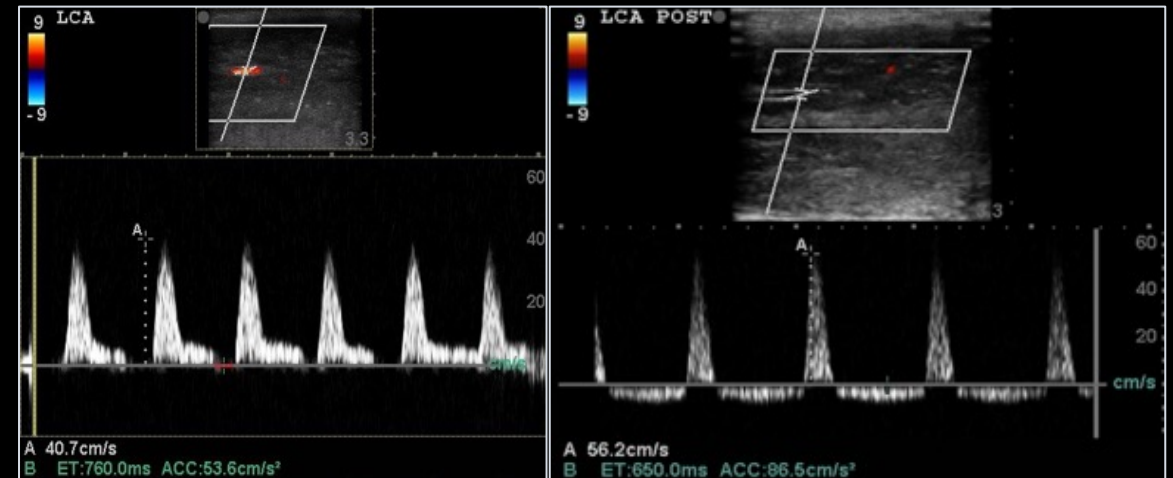- Office-based or radiology department exam, dependent on institutional workflow
- Dynamic test requires ICI of **vasoactive agent** (prostaglandin E1 – PGE1)
- Flaccid scanning only for trauma, priapism, prosthesis evaluation and optional for PD/ED eval
- High frequency linear transducer, slow flow Doppler settings
- Three components:
  - **Gray-scale** anatomic assessment: fluid collection, fibrosis, plaques, masses
  - **Color Doppler**: identify vascular flow
  - **Spectral Doppler**: arterial and venous waveform & velocity
- Patients can be intolerant to the probe if pain is severe (which can limit the study).



**Flaccid dorsal image**  
(scanning possible traumatic injury)

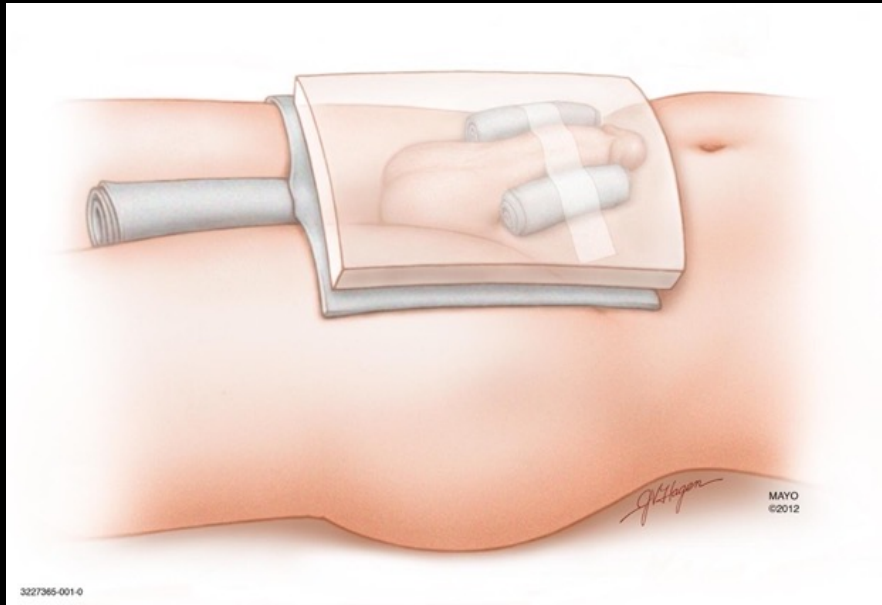


**Erect ventral image after ICI of PGE1 for PD evaluation**



- Normal left cavernosal artery before and after intracavernosal injection (ICI) of vasoactive agent. This is not typically performed in the emergency setting.
- Peak systolic velocity (PSV)  $\geq 35$  cm/s
- Resistive Index (RI)  $\geq 0.90$  or reversal below baseline

# COMPUTED TOMOGRAPHY



3227365-001-0  
From: Mayo Clinic Patient Education. Peyronies Disease (MC5885). Rochester, MN: Mayo Clinic, 2020, pp. 10 & 12; used with permission of Mayo Foundation for Medical Education and Research, all rights reserved.

Towels and tape may be necessary to obtain anatomic positioning for CT & MRI

CT can aid in the assessment of penile pathologies such as detecting calcifications for Peyronie disease, evaluation of penile prosthesis, abscesses and hematomas.

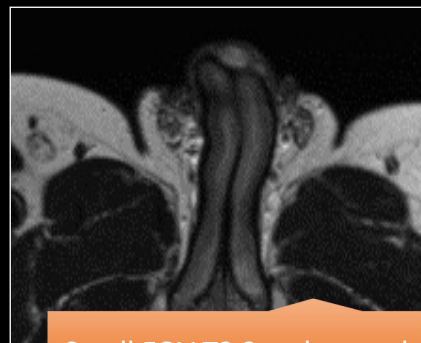
CT has low sensitivity for assessing detailed penile soft tissue findings, non-calcified plaques, fibrosis of tunica albuginea, and general inflammation due to decreased soft tissue contrast compared with US or MRI.

Advantages include fast acquisition, widespread availability and evaluation of additional structures that require urgent treatment in traumatic cases.

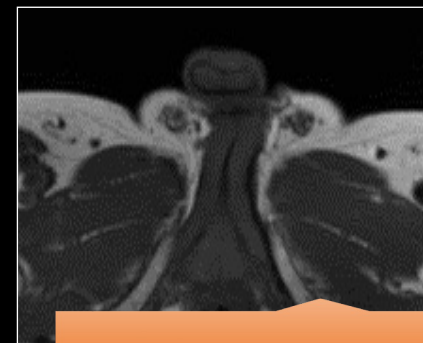


# MAGNETIC RESONANCE IMAGING

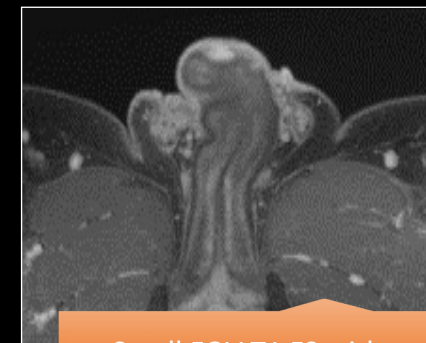- The penis is dorsiflexed against the abdomen and held in place with an overlying towel and tape.
- Small field of view (FOV) adjusted to the penis. Sequences obtained in axial (AX), coronal (COR) and sagittal (SAG) planes, fat saturation (FS) and with contrast (post Gd).
- MRI provides excellent visualization of erectile bodies, penile fascial layers, inflammation, and non-calcified plaques in the septum and tunica albuginea.
- Difficult to differentiate infection/inflammation from neoplasm without contrast.
- Access can be limited compared to CT and US.



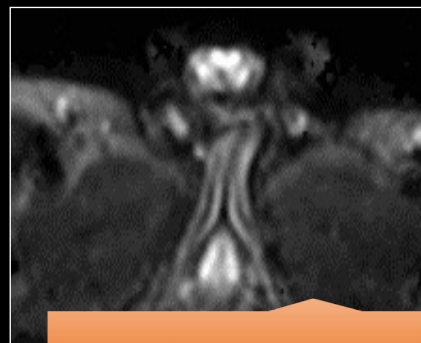
Small FOV T2 3 orthogonal planes, thin-section



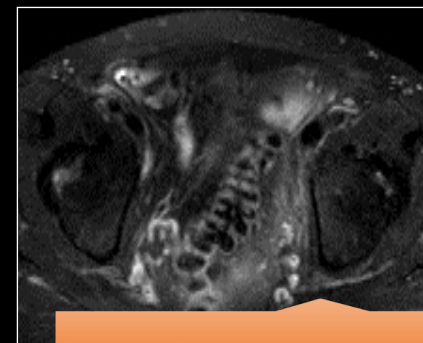T1 - without and FS



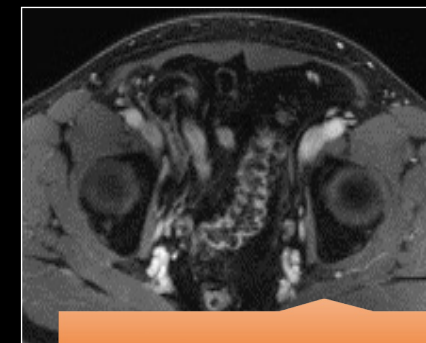
Small FOV T1 FS with contrast - 3 planes



DWI (B50, B400, B800)



Large FOV T2 FS



Large FOV T1 with contrast

# TRAUMATIC INJURIES

---

Blunt or penetrating injuries to the penis can result in penile hematomas and fracture.

---

**Penile fractures** occur when the corpus cavernosa is injured and results in a tear of the tunica albuginea. This urologic emergency requires immediate surgical exploration. Urethral injuries can also be present.

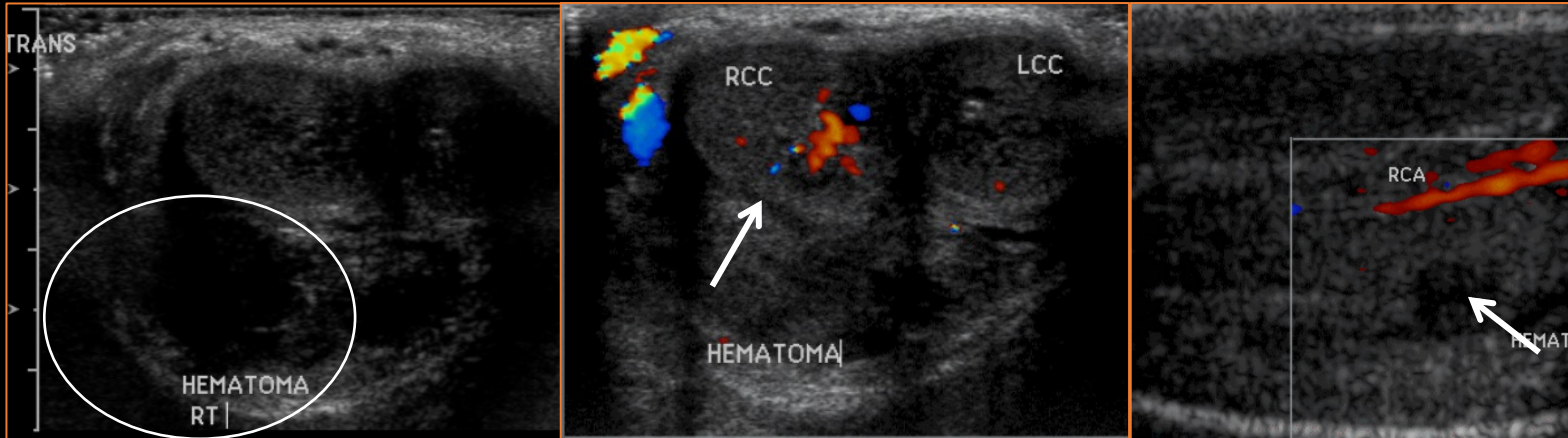
---

**Hematomas** are usually present with penile fractures but can also be present without disruption of the tunica albuginea. If tunical albuginea is intact, the patient can be treated conservatively.

---

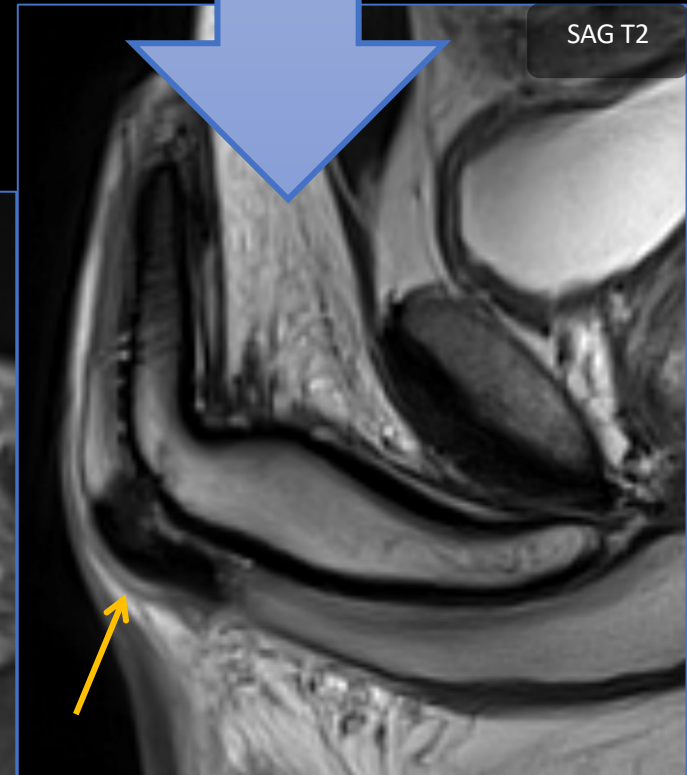
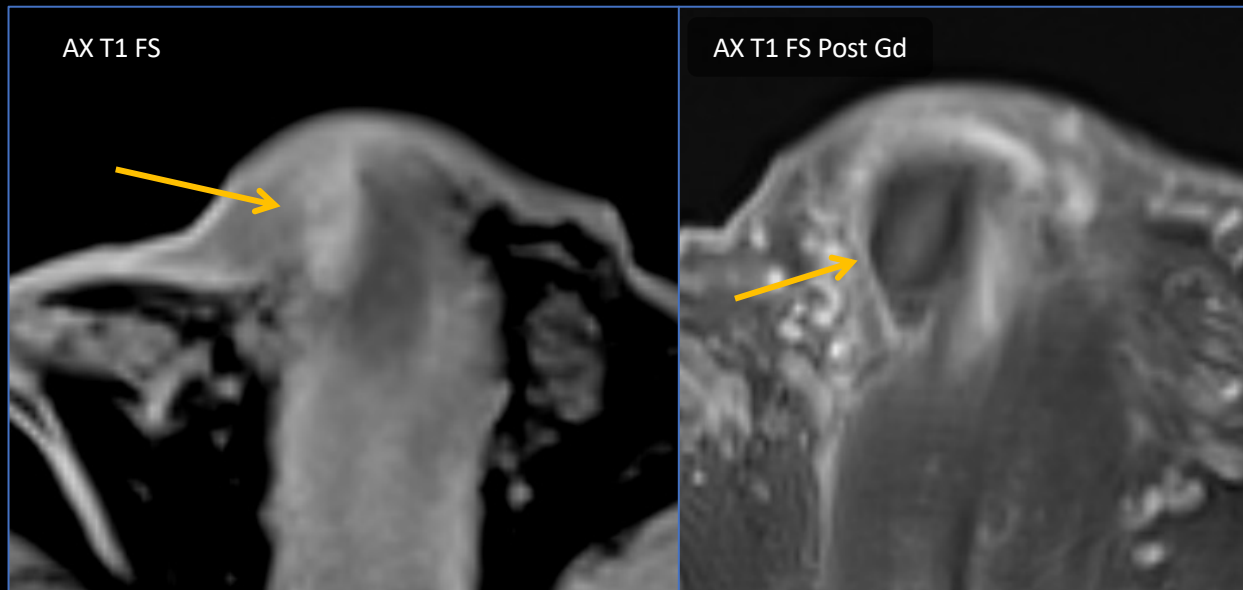
US provides a quick assessment of the penile structures, although some patients may not tolerate the pressure required for an adequate exam. MRI can provide better soft tissue assessment in those cases.

# TRAUMATIC INJURIES – Hematoma



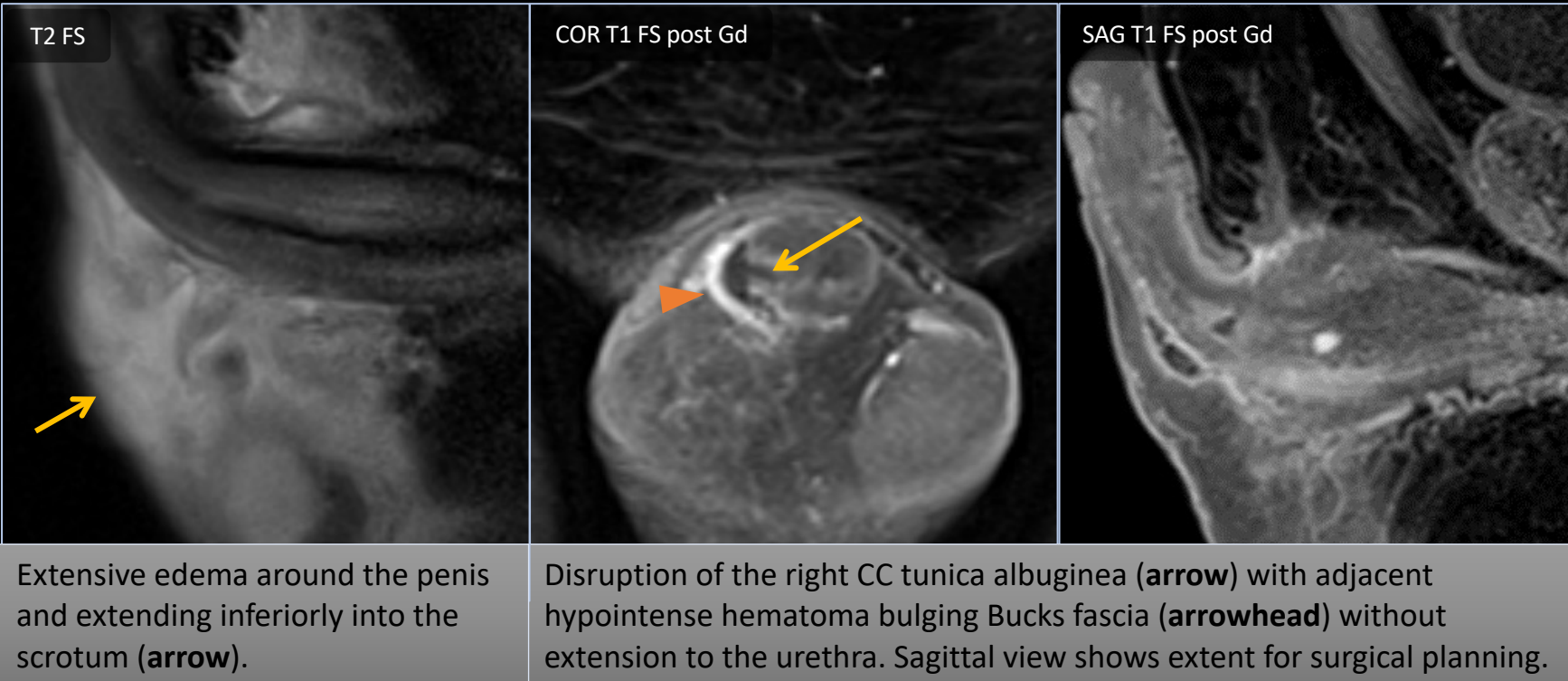
US demonstrating right intracavernosal (**arrows**) and right ventral (**circle**) hematomas. The TA and corpora spongiosa are intact.

MRI demonstrating a hematoma in the corpus spongiosum (**arrows**) without disruption of the TA. Notice the T2 hypointensity (**SAG T2**), T1 hyperintensity (**AX T1 FS**) and lack of enhancement





# TRAUMATIC INJURIES – Fracture



Patients may present with a combination of pain, detumescence, swelling, or hematoma.

**Surgical repair** is necessary to prevent abscess, fibrosis, deformity, urethral stricture, & erectile dysfunction.

Fractures often occur due to **sudden bending**, resulting in tear of the tunica albuginea surrounding one or both of the corpora cavernosa.

The erect penis is at higher risk because of **thinning of the tunica albuginea during tumescence**.

Urethral injury can occur in up to 20% of these cases.

# INFLAMMATION

---

Penile inflammation is typically caused by **infection**, although other etiologies in the inflammatory spectrum should also be considered.

---

Penile infections are uncommon but occur primarily in diabetic patients or the post operative setting.

---

Higher mortality if the infection involves the corpora cavernosum and spongiosum.

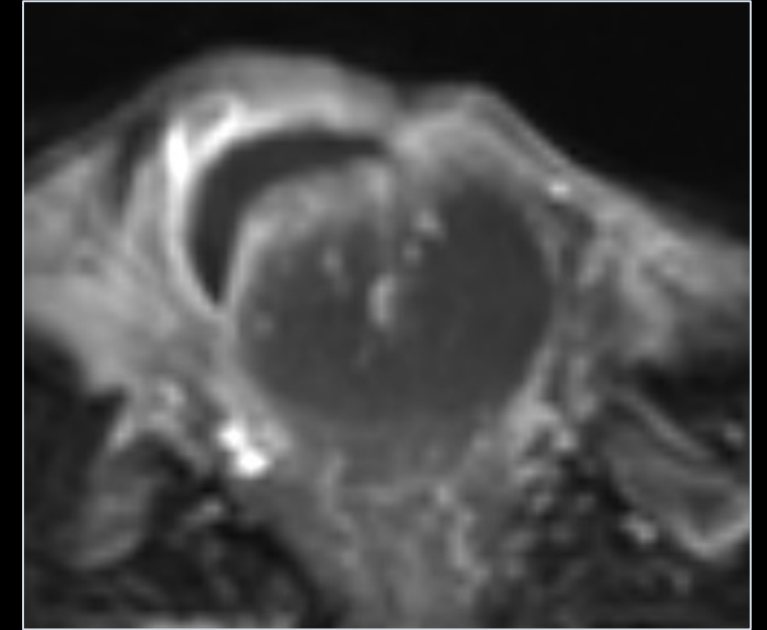
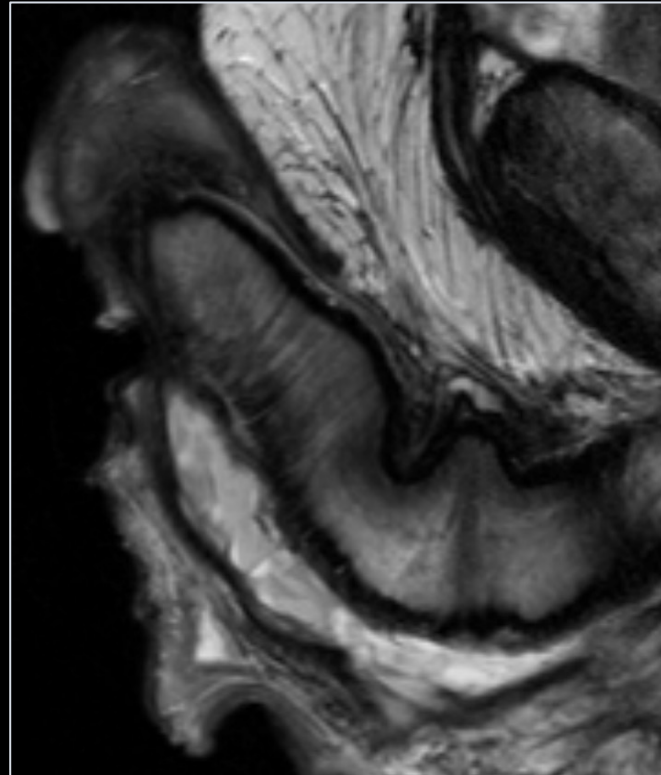
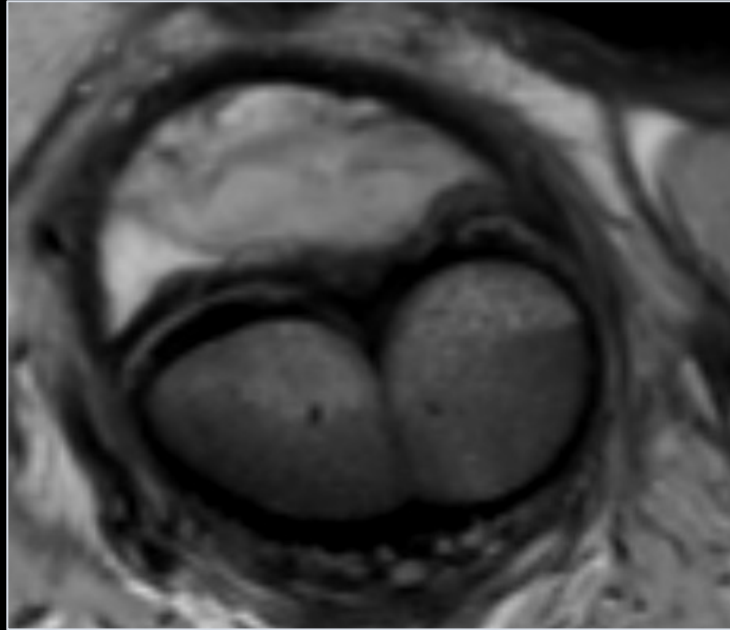
---

Extent of disease is better assessed with MRI, although distinguishing from inflammation and local malignancy can be challenging due to similarities on imaging.

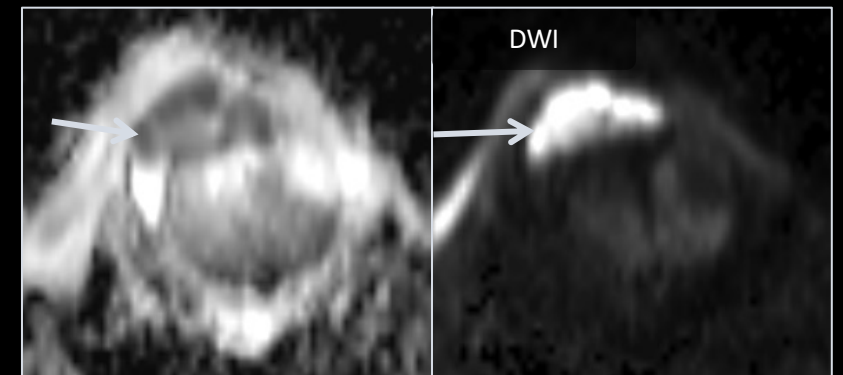
---

Inflammatory bowel disease can cause complex fistulas that extend to the penile structures.

# INFLAMMATION – Abscess



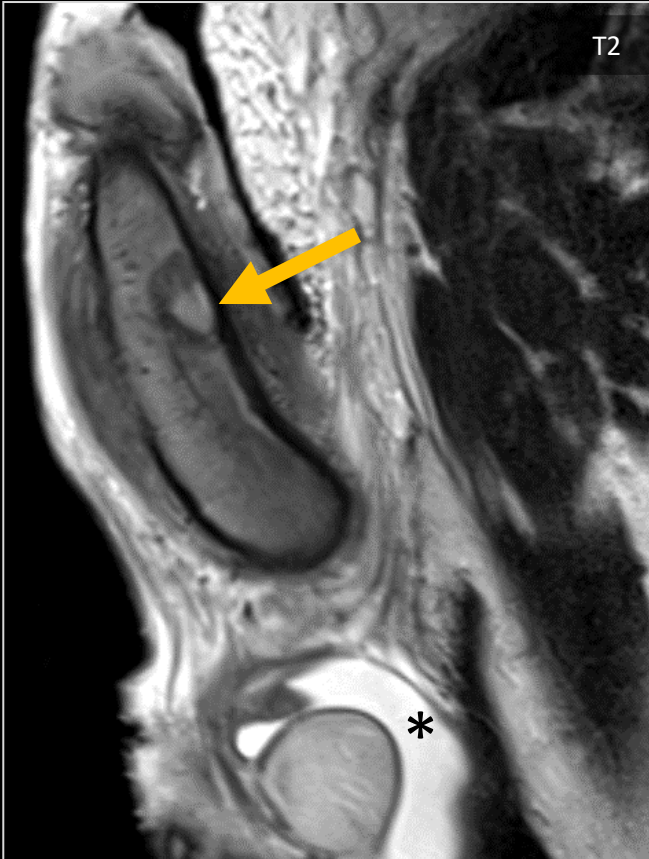MRI of a ventral penile abscess post urethroostomy with T2 hyperintense fluid collection (**AX and SAG T2**), rim enhancement (**AX T1 post Gd**) and restricted diffusion (**ADC, DWI**) along the ventral shaft of the penis.





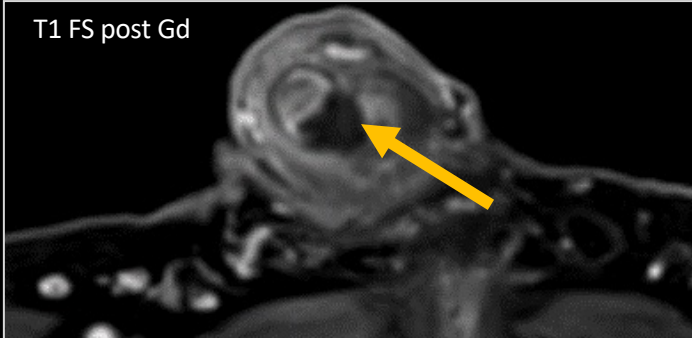
# Mass or Abscess?

Patient with myelodysplastic syndrome presented with fevers, penile pain and swelling



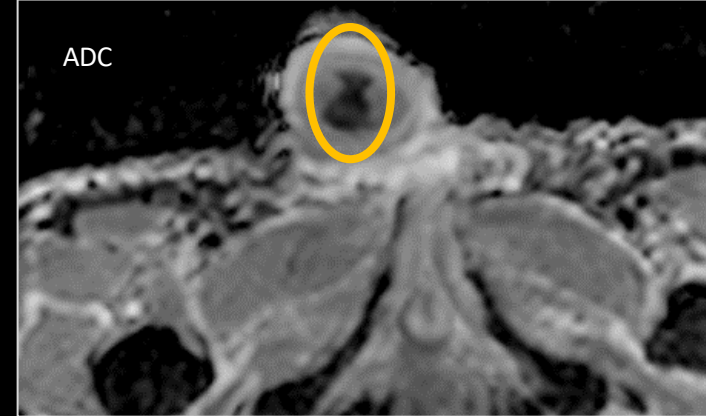
Sagittal T2WI shows a heterogeneous lesion in the mid penis (arrow) and a moderate hydrocele (\*)

T1 FS post Gd

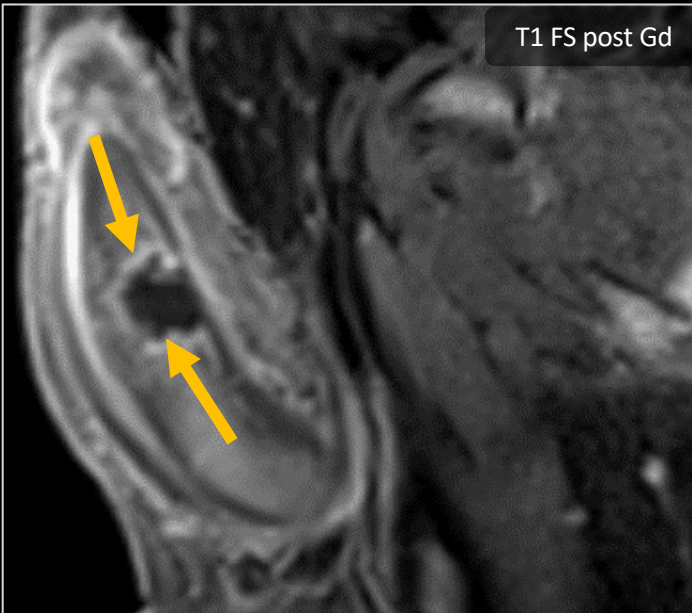


Axial post contrast T1FS show no internal enhancement in the lesion (arrow) that splays apart the corpora cavernosa

The lesion has restricted diffusion (circle)

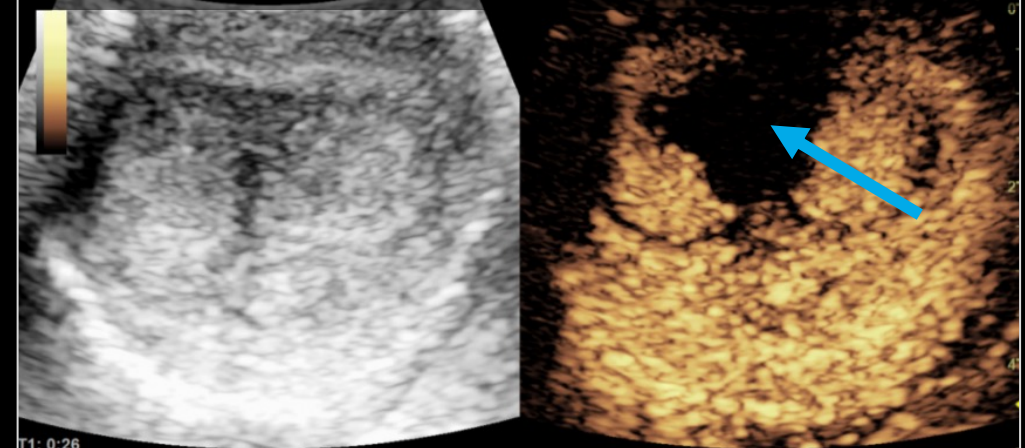


T1 FS post Gd



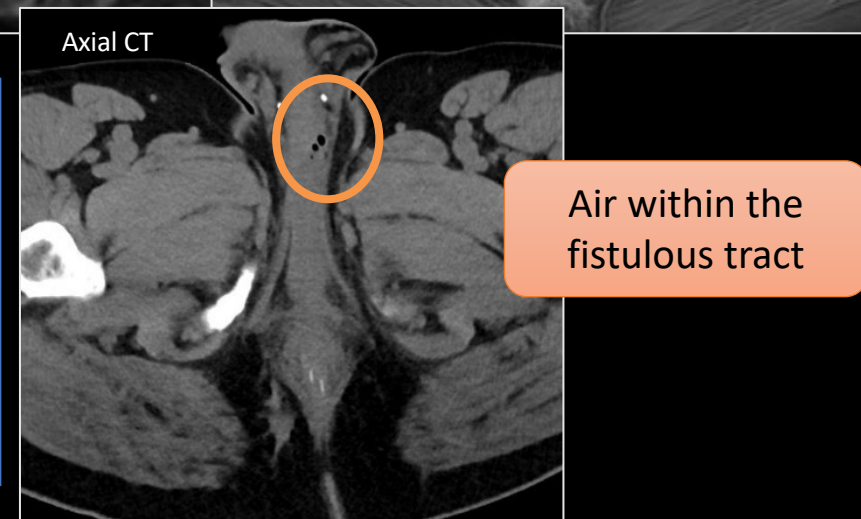
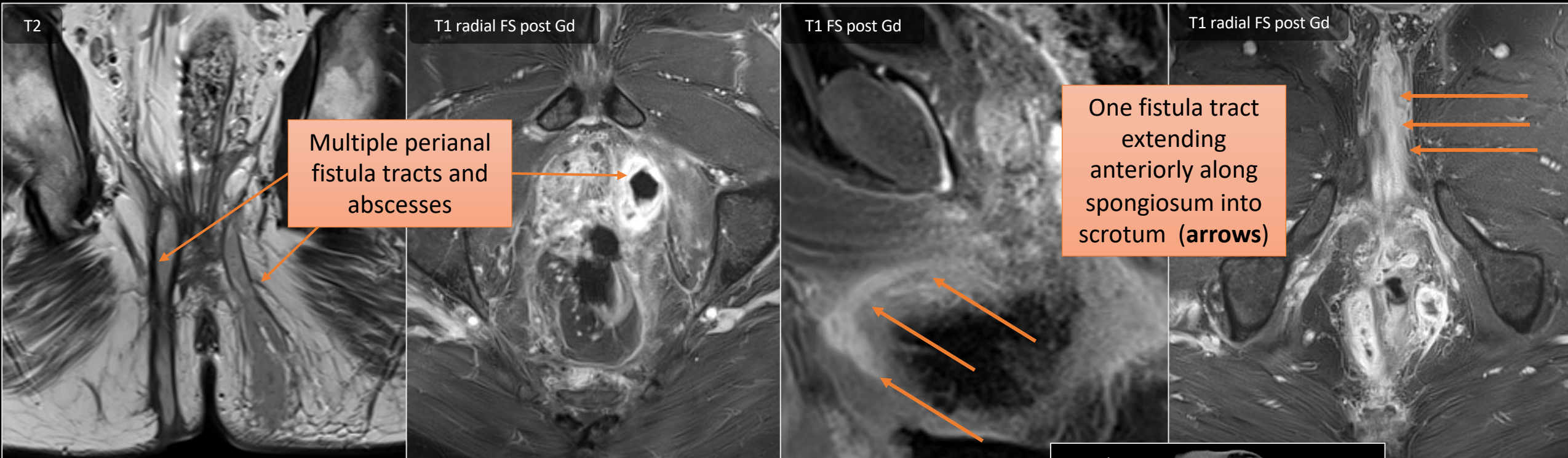
Sagittal post contrast T1FS show irregular rim enhancement around the lesion (arrows)

The lesion could not be identified with ultrasound for sampling, so **contrast enhanced ultrasound** was used to target the nonenhancing area (blue arrow) for biopsy, with results of **dense inflammatory infiltrate**





# INFLAMMATION – Complex Fistulas

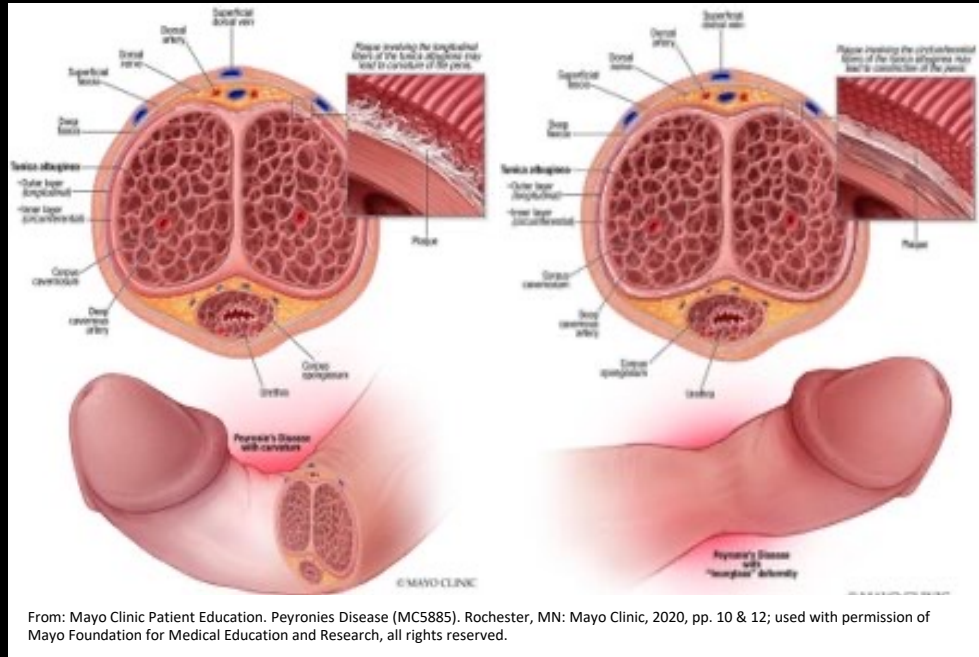


Patient with history of Crohn disease who developed multiple complex fistulas, some involving the genitourinary structures.

Careful delineation of all fistula tracts is critical to patient management and surgical planning.

# INFLAMMATION – Peyronie Disease

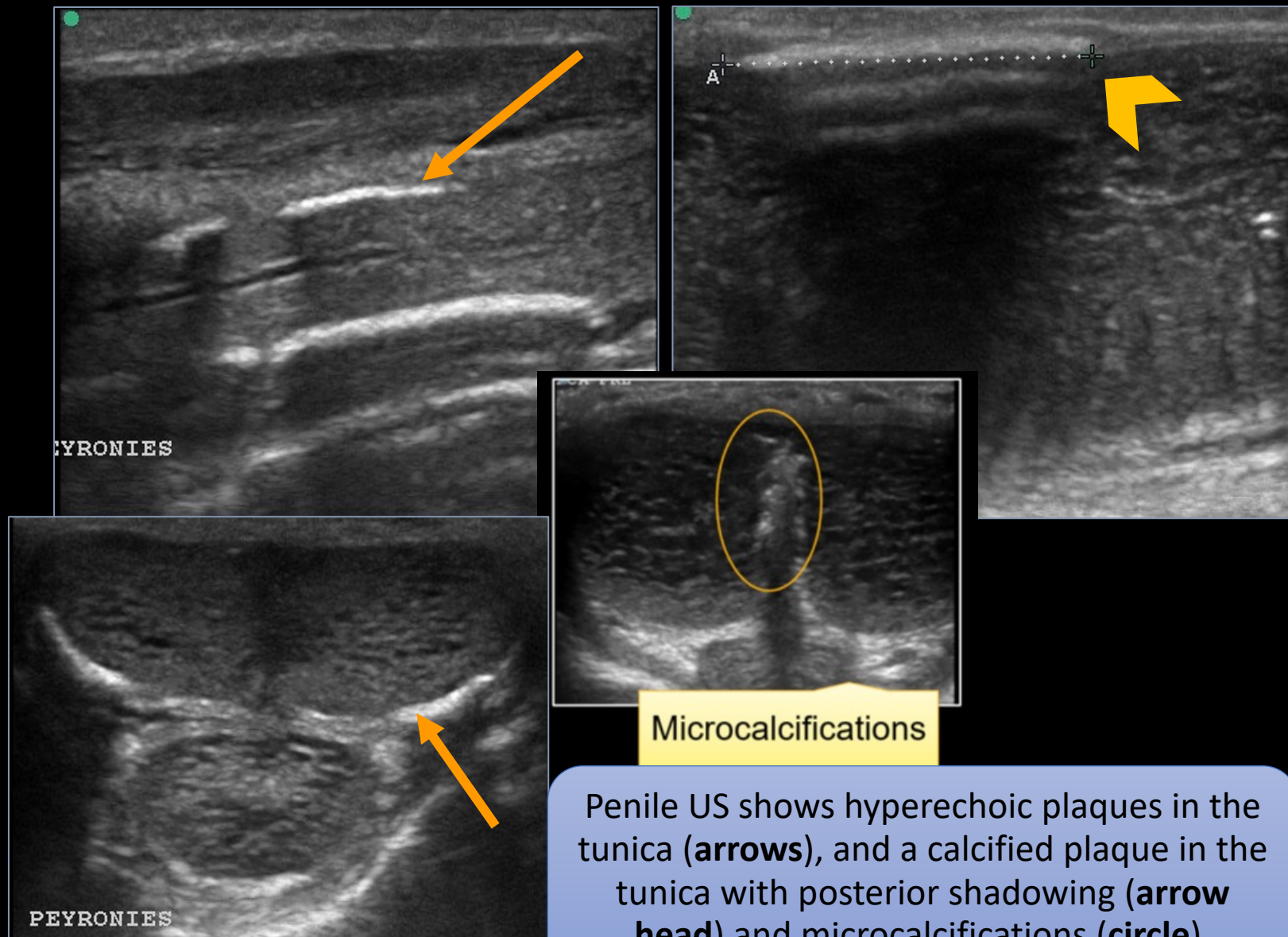
- **Poorly understood – disordered wound healing**
- Microtrauma to erect penis
- Proliferative fibrotic reaction in the **tunica albuginea** leads to deformities.
- Bleeding, fibrin, and inflammatory cells may lead to upregulation of cytokines and plaque formation.
- May have an autoimmune component.
- Two phases:
  - **Acute** inflammatory phase with painful erections and soft plaques or nodules, often lasts 12-18 months
  - **Fibrotic** phase with hard palpable plaques causing stable deformity and/or shortening but little to no pain



From: Mayo Clinic Patient Education. Peyronie Disease (MC5885). Rochester, MN: Mayo Clinic, 2020, pp. 10 & 12; used with permission of Mayo Foundation for Medical Education and Research, all rights reserved.

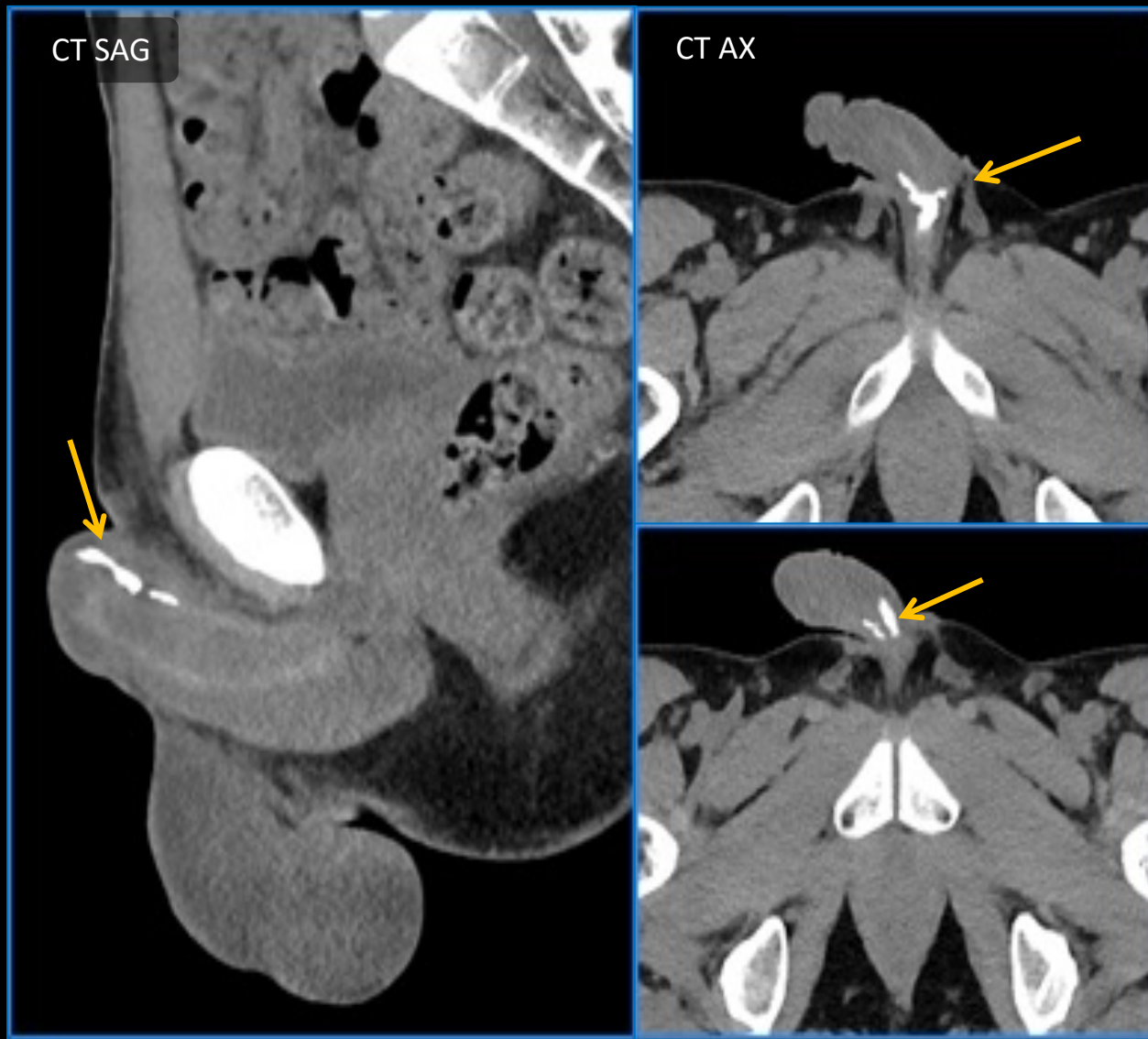
# Peyronie Disease – Ultrasound

- Localize & characterize plaque
  - Acoustic shadows
  - Microcalcifications
  - Confluent calcified plaques
- Extent & distribution can be obscured by acoustic shadowing
- Thickness indeterminant
- Degree of calcification indeterminant





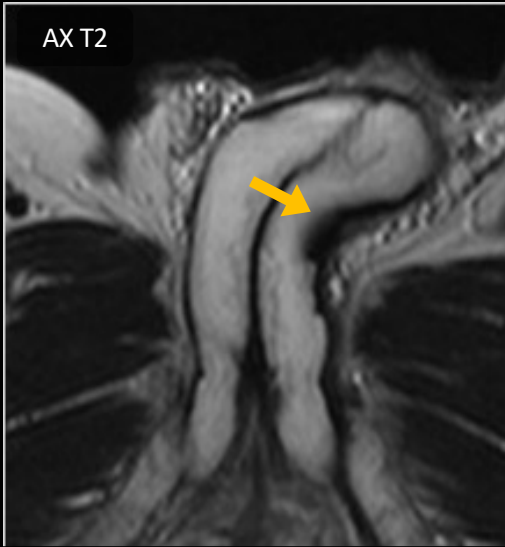# Peyronie Disease – CT



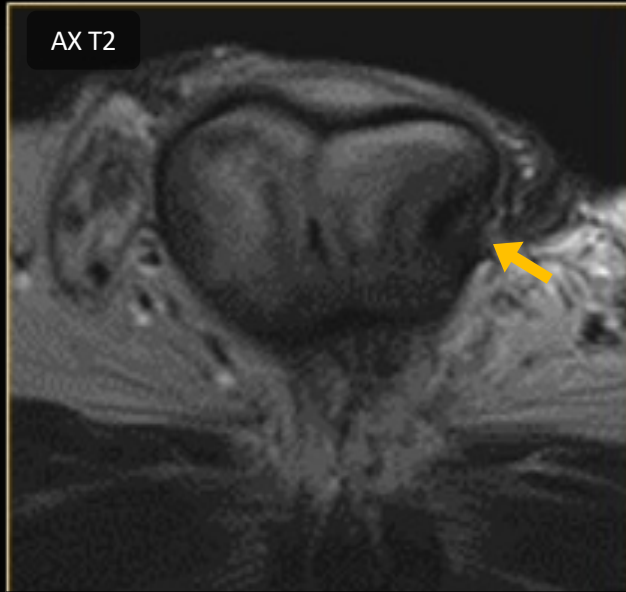
- Noncontrast CT pelvis with thin multiplanar reformatting to map extent of calcified plaques allowing for surgical planning.
- Calcified plaques (arrows) can occur at any point during disease evolution and does not correlate with chronicity or severity, but patients with calcified plaques are less likely to respond to nonsurgical therapies.



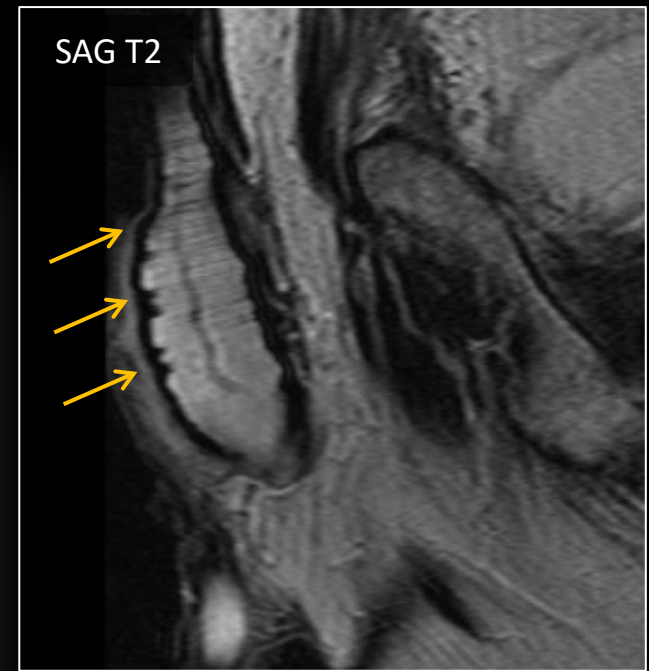
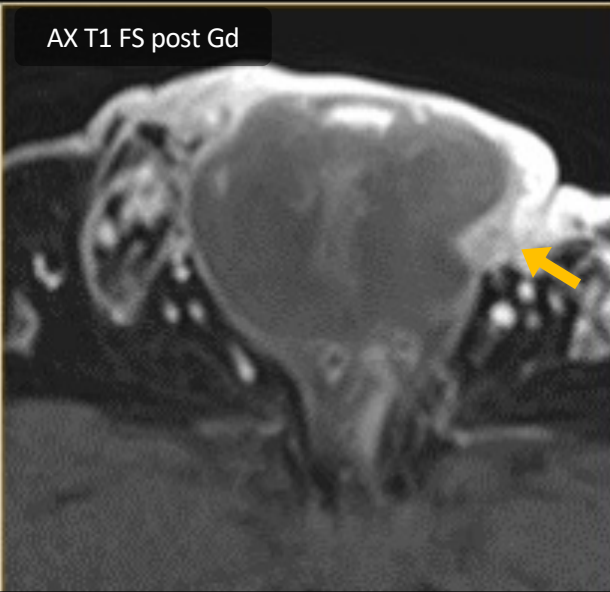
# Peyronie Disease – MRI



T2 axial image shows left focal plaque (**arrow**) with leftward deviation of the penis



Axial T2 and T1 FS post contrast left lateral plaque with focal T2 hypointensity and enhancement (**arrows**).



Sagittal image shows T2 hypointense irregular thickening of the tunica albuginea (**arrows**) along the penile shaft

- MRI helps assess the thickness, extent and inflammatory enhancement of the disease.
- Scarring results in penile indentation, shortening, curvature, and erectile dysfunction.

## **Nonsurgical Management:** less effective for calcified plaque, extensive curvature

- Intralesional collagenase clostridium histolyticum injection
- Penile tension devices
  - No convincing evidence for oral therapies other than for pain management

## **Surgical Management:** most rapid results, need to be in quiescent phase

- Tunica plication or plaque excision for patients with adequate erectile function
- Penile prostheses for patients with concomitant erectile dysfunction not responsive to other therapies

# VASCULAR

---

Most acute vascular abnormalities can present with acute penile pain.

---

**Low flow priapism** (ischemic) results from failure of the detumescence mechanism leading to a painful ischemic state. If not treated, this condition results in erectile dysfunction.

---

**High flow priapism** is uncommon and results from uncontrolled arterial inflow, often from genitourinary trauma. Typically presents with painless erection and does not require emergent treatment.

---

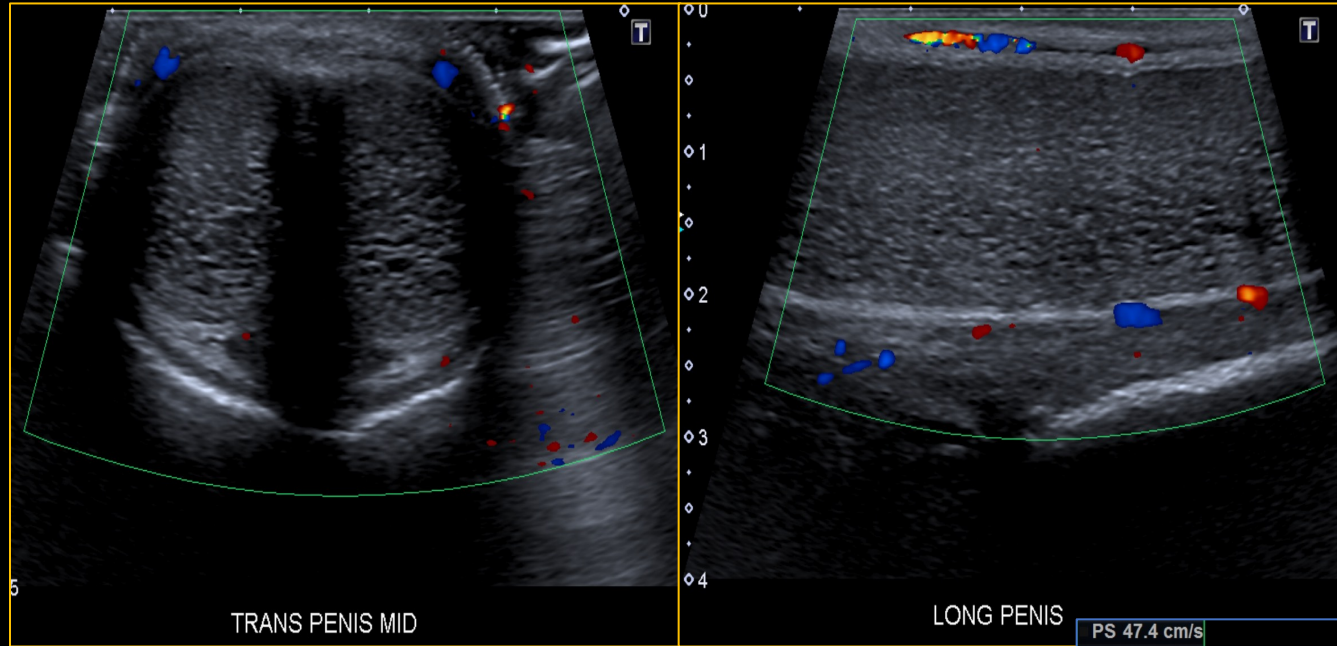
**Superficial venous thrombosis** (Mondor's disease) is a rare and self-limiting acute thrombosis of the superficial dorsal vein of the penis that usually presents as a painful palpable mass.

---

**Thrombosis of the corpus cavernosum** is a rare and poorly understood disease. It may present as a palpable perineal or penile painful mass.

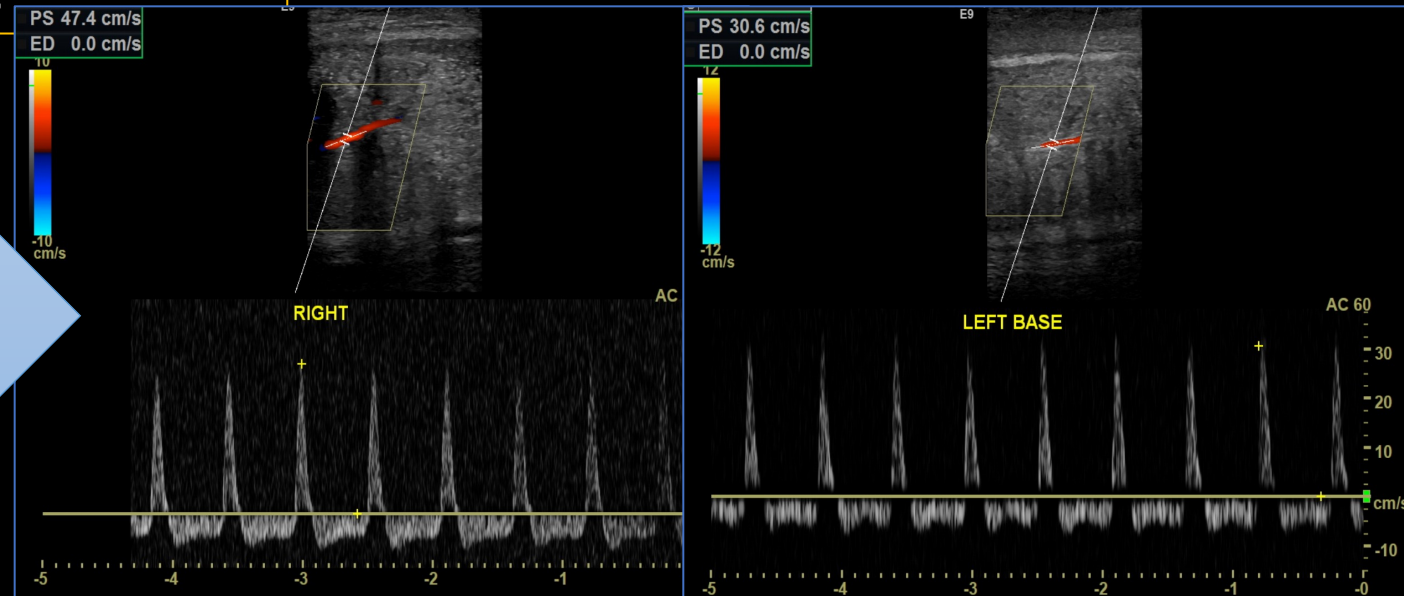
---

# VASCULAR – Priapism: Low Flow



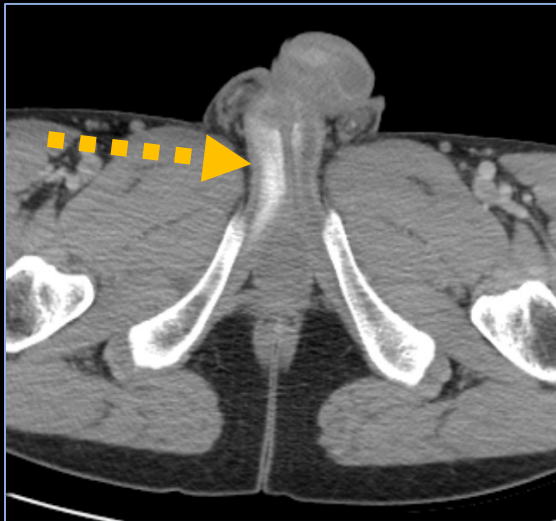
Low flow priapism. Color Doppler US shows **absent flow** in the cavernosal arteries. The patient subsequently underwent injection, irrigation and aspiration for the ischemic priapism.

Low flow priapism: patient with erectile dysfunction post ICI with progressive painful erection that was unresponsive to phenylephrine. Color Doppler US found **high resistance waveforms** from the cavernosal arteries. Deoxygenated blood was confirmed.

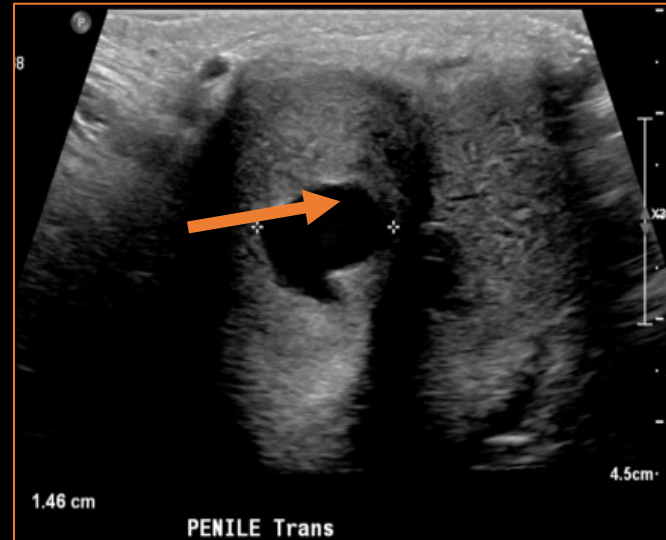


# VASCULAR – Priapism: High Flow

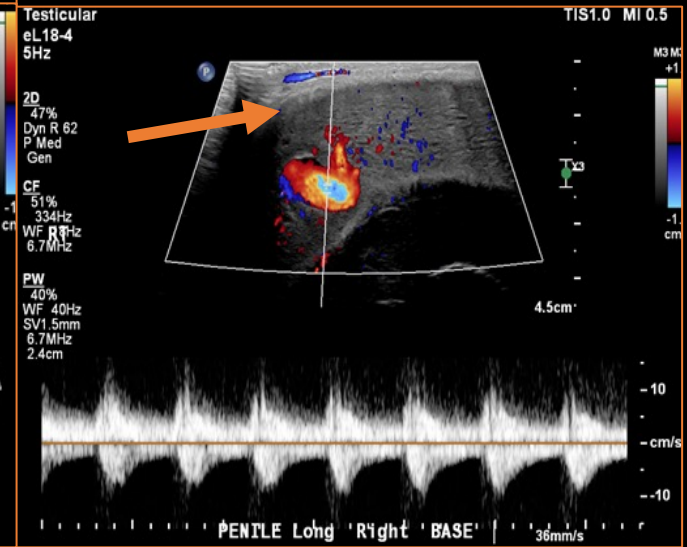
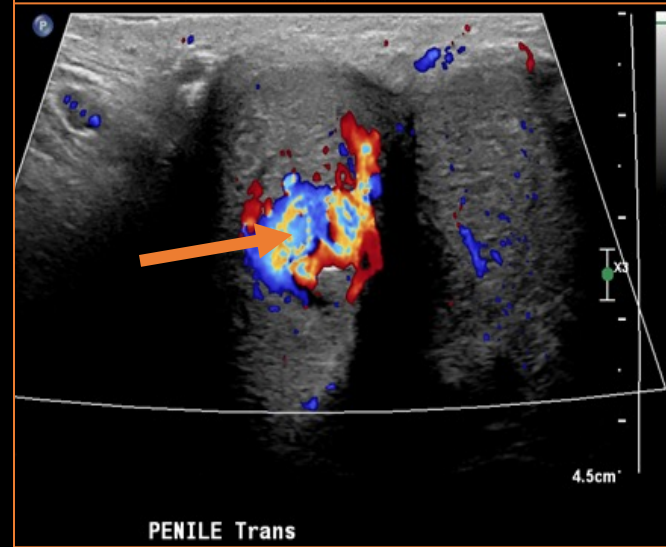
- High flow priapism typically presents as painless erection but should be differentiated from low flow.
- Trauma to the cavernosal artery leads to formation of **arterio-cavernosal fistula** between a cavernosal artery and lacunar spaces of the penis.
- Angiogram remains the gold standard for diagnosis with embolization as the preferred treatment method.



Axial CT shows asymmetric enhancement of the right corpora cavernosa (**dotted arrow**).



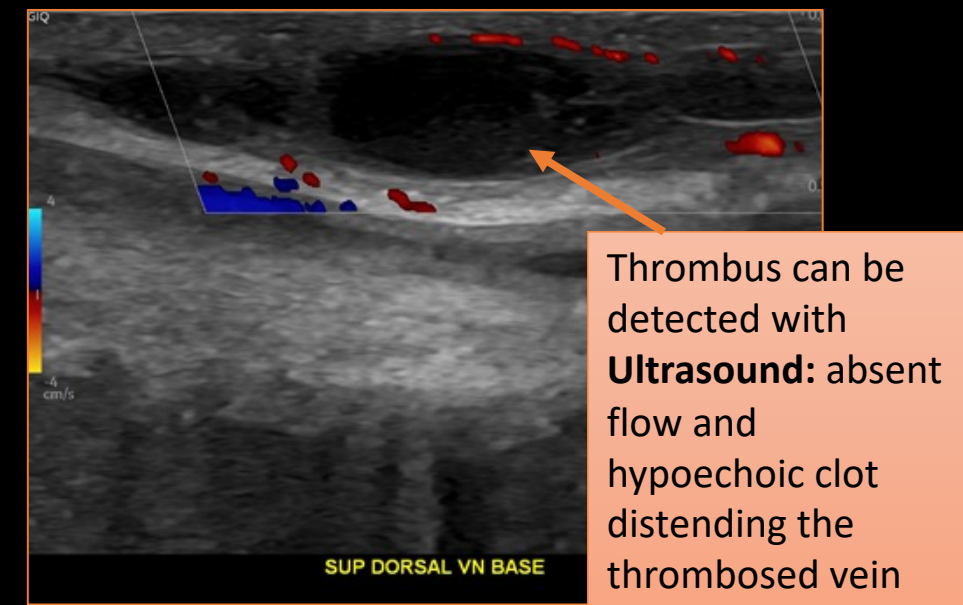
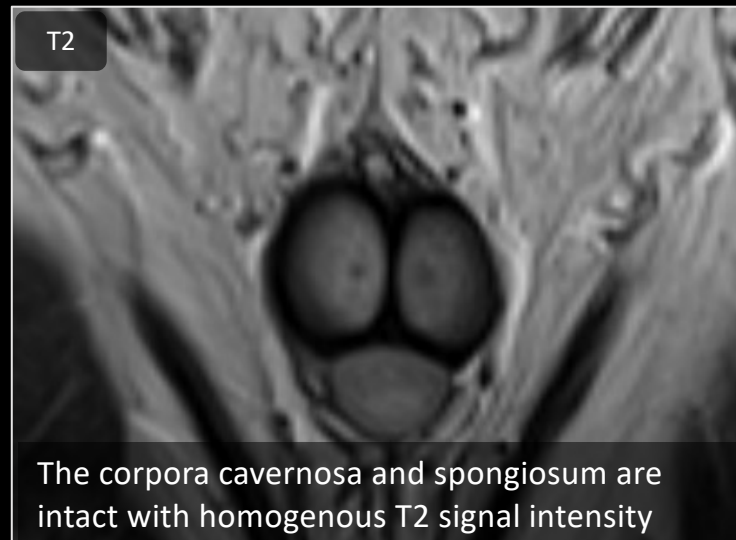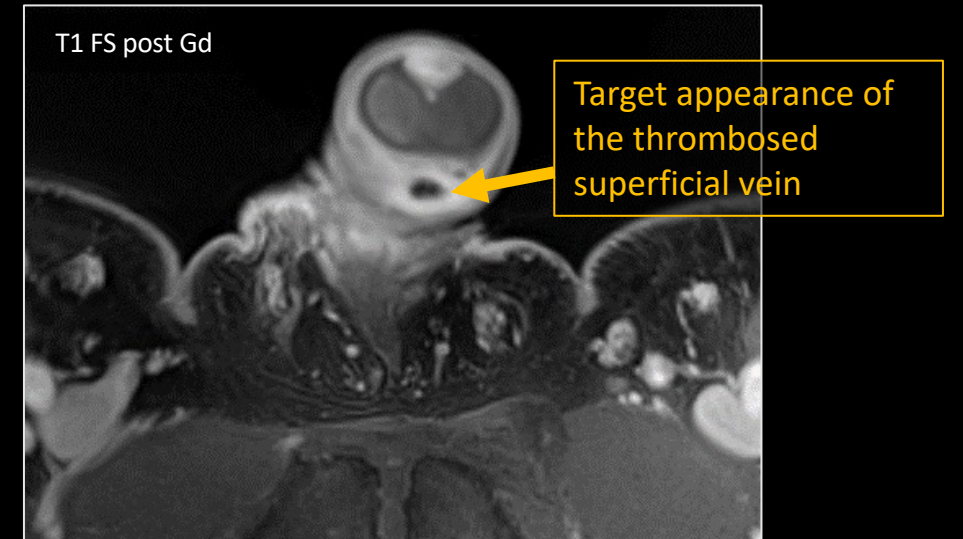
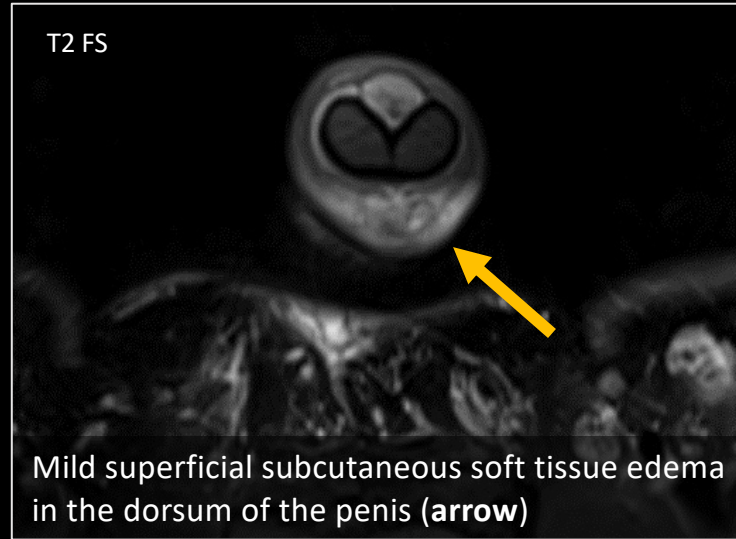
Patient post trauma with hematuria and erection: US shows a right arteriocavernosal fistula with pseudoaneurysm (**arrows**).





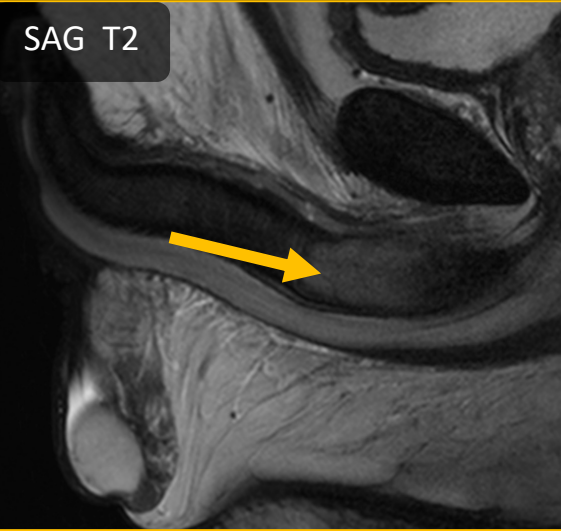# VASCULAR - Superficial Venous Thrombosis

- Very low incidence, but may be underreported
- Can present with pain and/or a palpable cord along dorsal aspect of penis
- **Risk factors:** vigorous intercourse, genital trauma, infection, pelvic malignancy, hypercoagulable state
- **Differential diagnosis:** penile fracture, Peyronie's, sclerosing lymphangitis
- **Management:** avoid intercourse, NSAIDs; usually resolves in 1-6 weeks

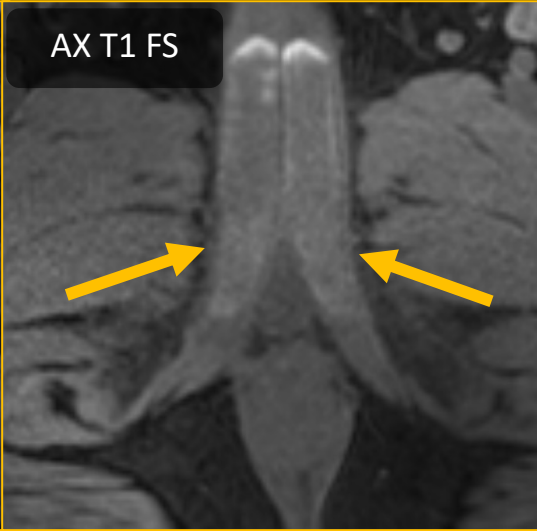


# VASCULAR – Thrombosis of the Corpora Cavernosa

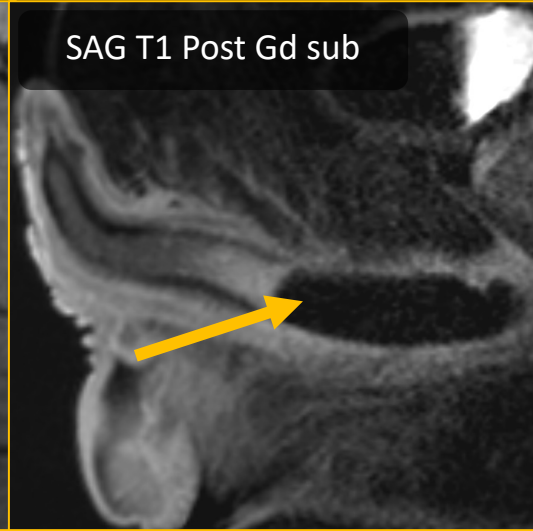
SAG T2



AX T1 FS



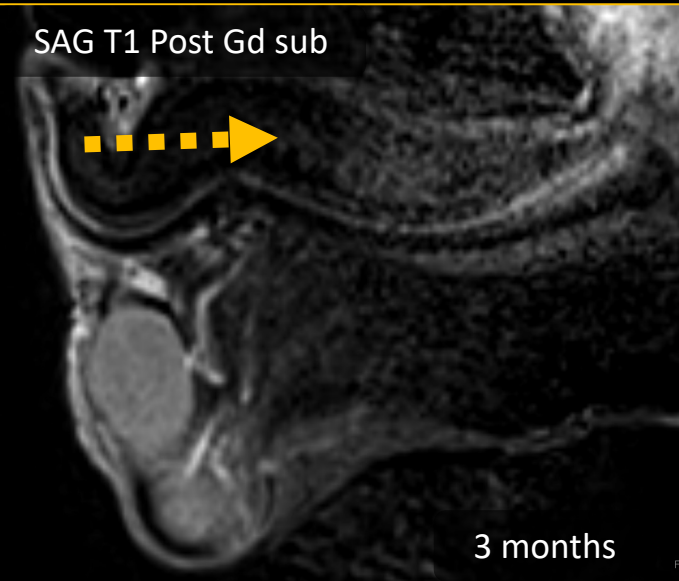
SAG T1 Post Gd sub



MRI of acute bilateral corpora cavernosa partial segmental thrombosis (**arrows**). Notice the sharp delineation, suggestive of fibrous septa.

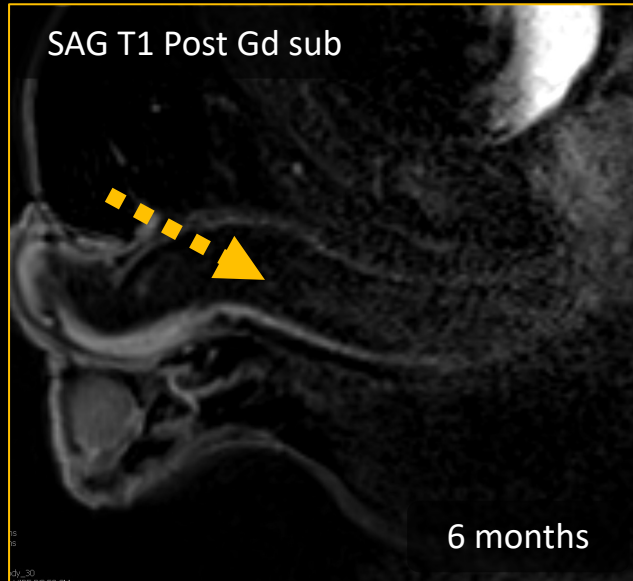
Current recommendations include conservative treatment with **anticoagulation**. Therapy-resistant cases, surgery remains a viable option.

SAG T1 Post Gd sub



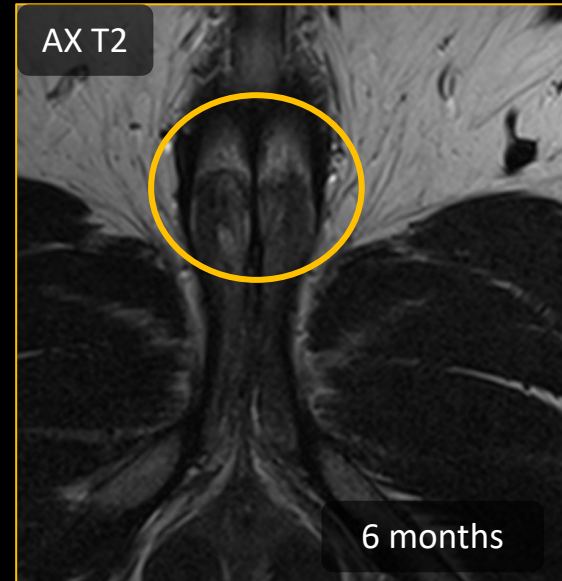3 months

SAG T1 Post Gd sub



6 months

AX T2



6 months

**3 and 6 months** of anticoagulation therapy. Decreased clot burden at 3 months and completely resolved by 6 months (**dotted arrows**). The fibrous septa remain present (**circle**).

# PENILE PROSTHESIS COMPLICATIONS

---

CT or MRI can clarify difficult cases and aid in planning surgical intervention.

---

**Most current IPP are MRI compatible:** Older semi-rigid IPP composed of metal wires are no longer manufactured (OmniPhase and Duraphase)

---

**Causes of painful prostheses** include infection, device malpositioning, improper sizing, buckling, erosion, cylinder cross-over, and herniation

---

**Post procedural fibrosis** of the tunica albuginea results in penile deformity, shortening, curvature, *pain* and restricted inflation. Patients with history of Peyronie disease or who have undergone multiple operations have increased risk.

---

**Device malfunction** includes leak, aneurysm, autoinflation, component detachment and can be diagnosed clinically but imaging can help determine surgical approach.



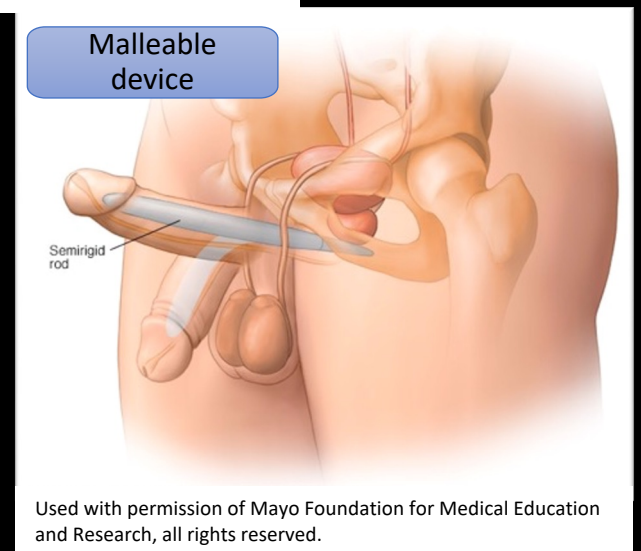
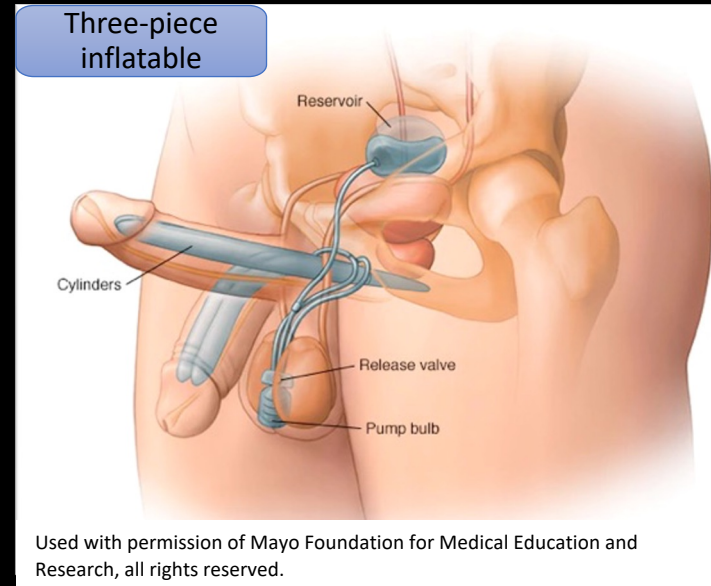
# Implantable penile prosthesis (IPP)

Effective treatment for erectile dysfunction that does not respond to medical and noninvasive therapy

- **Two- or three-piece inflatable** – most natural appearance
  - Low failure rate
  - Decreased incidence of cylinder crossover, erosion, perforation
  - Placement may be complicated by prior surgery
- **Semirigid** – difficulty operating the scrotal pump or have contraindications to abdominal reservoir placement
  - Paired bendable cylinders
  - Malleable, mechanical, or silicone
  - High risk of erosion

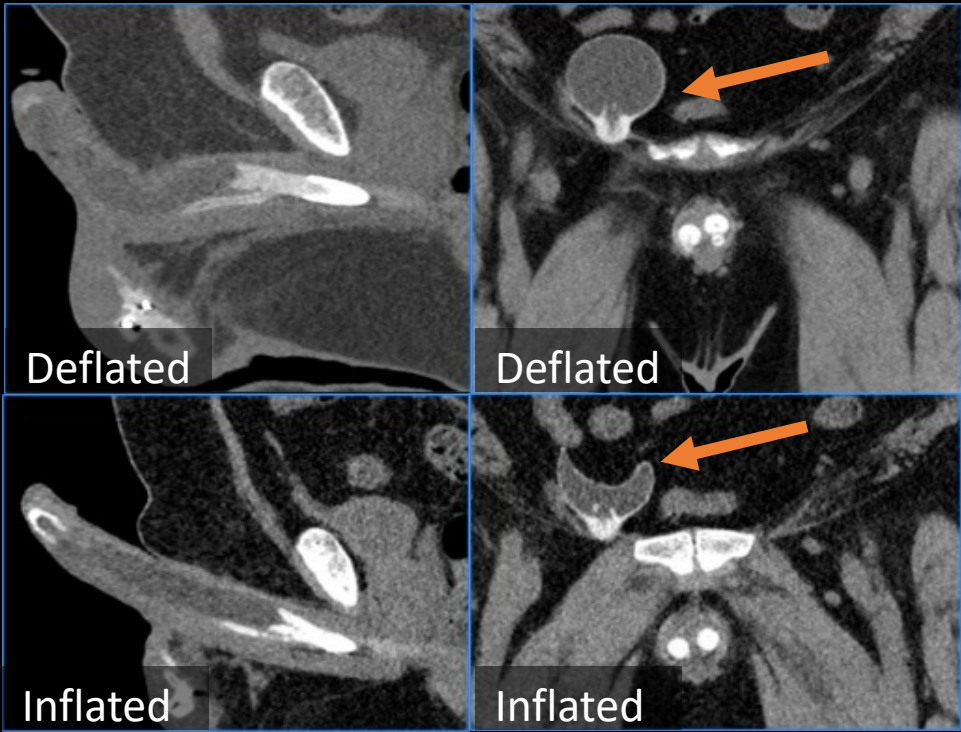
## Surgical Procedure:

- Expose and dilate the corpora cavernosa to accommodate the cavernosal components
- Measure corporal length to select device size, with length adjusted by the rear tip extenders
- Test inflation to check symmetry and ensure no buckling or crossover
- Scrotal pump placed in subcutaneous pouch & reservoir into space of Retzius via penoscrotal incision

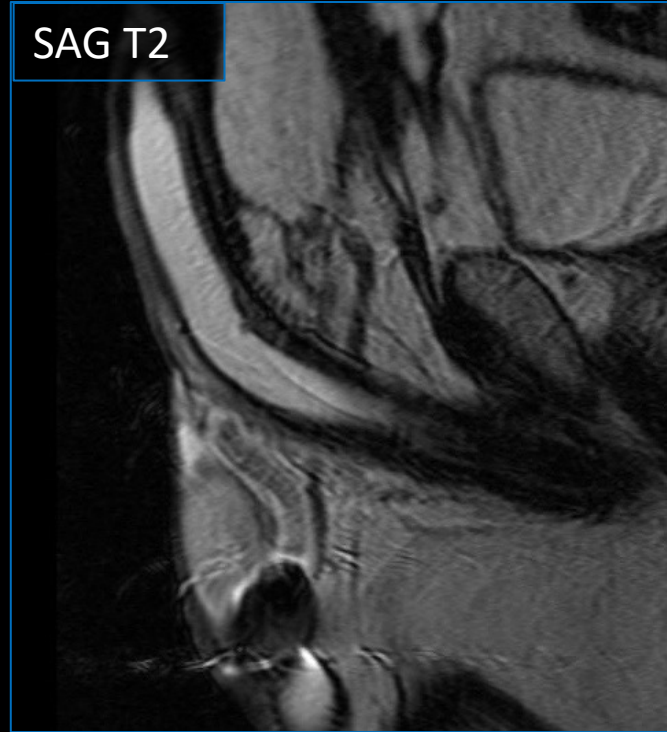



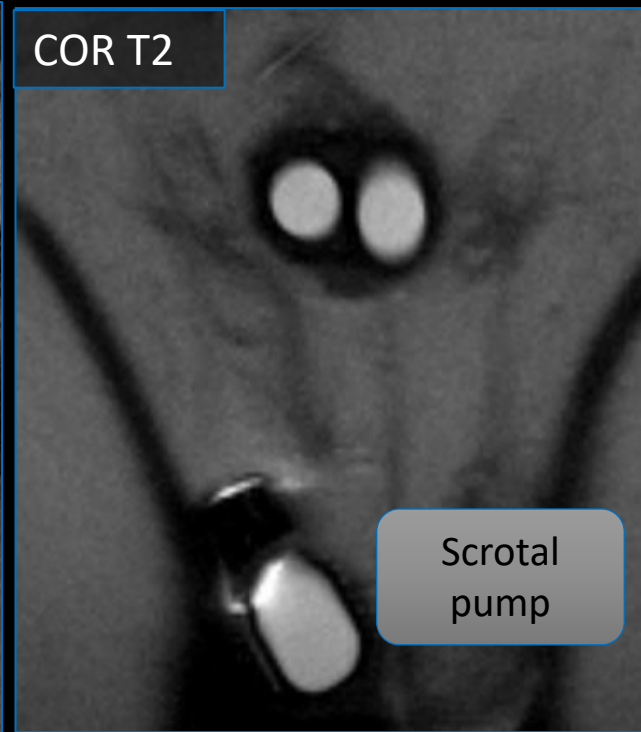
# Normal penile prosthesis



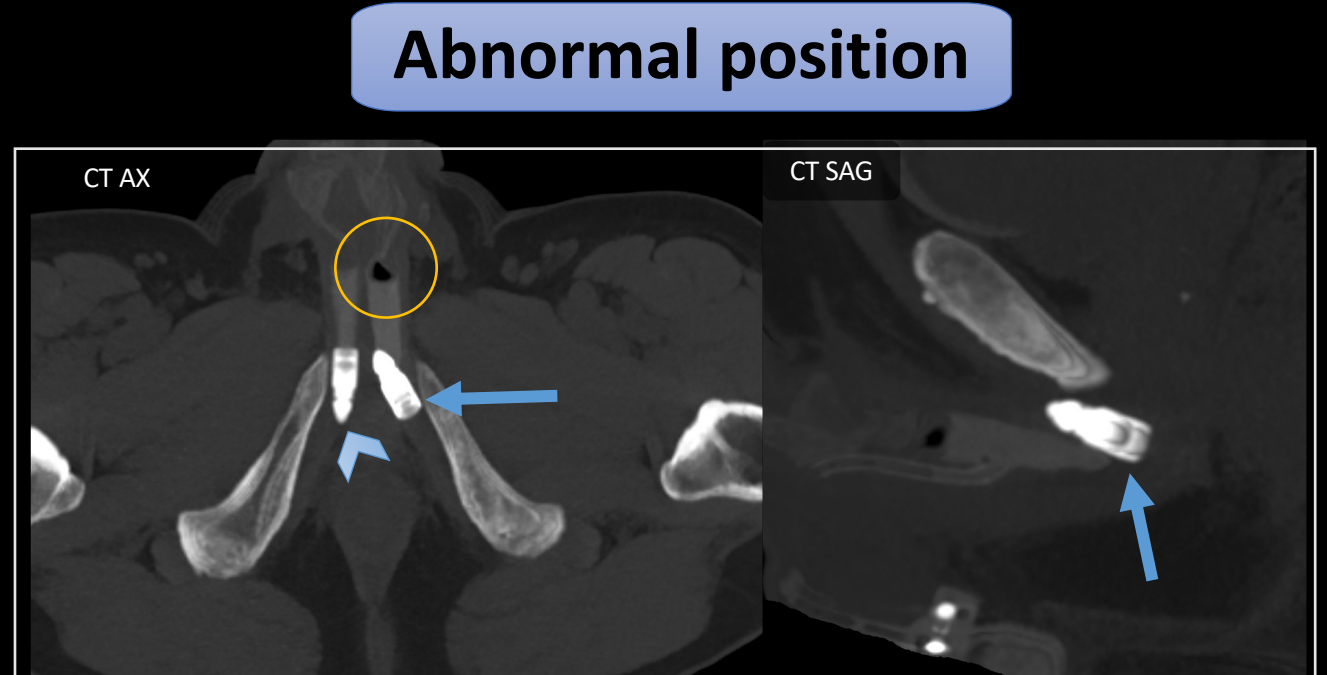
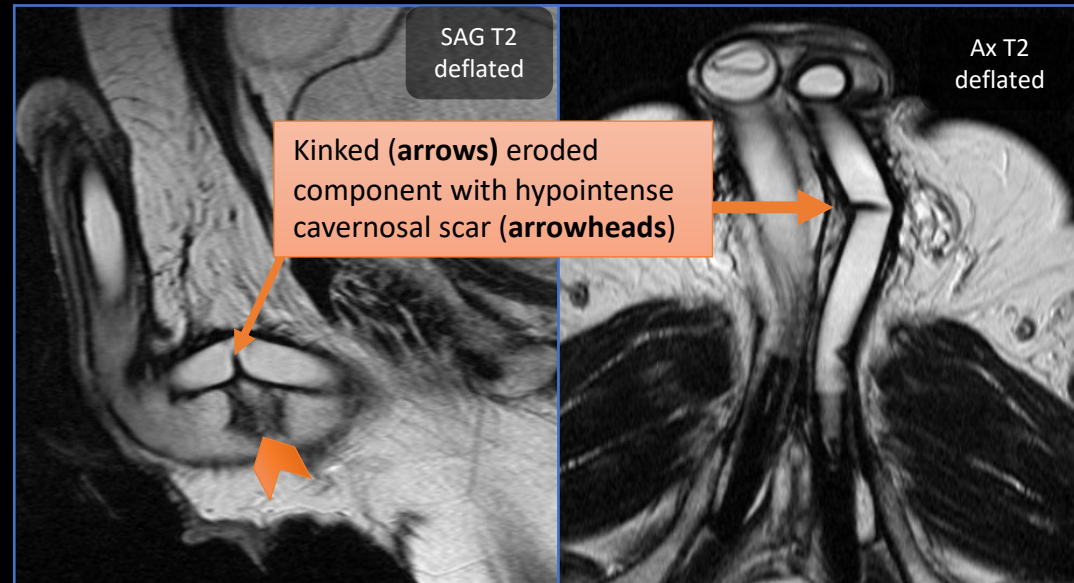
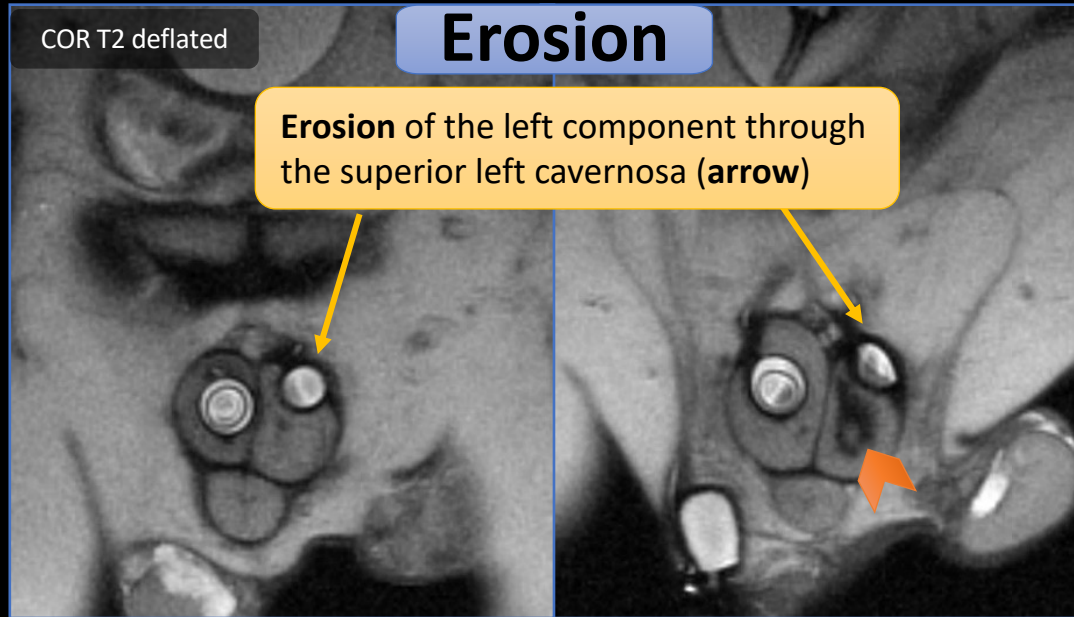
- Identify all components of the implant
- Check component positioning, including the reservoir (arrows) and scrotal pump



- After inflation, cylinders should have smooth appearance and the reservoir should be decompressed
- Cylinders should be centered in the cavernosa

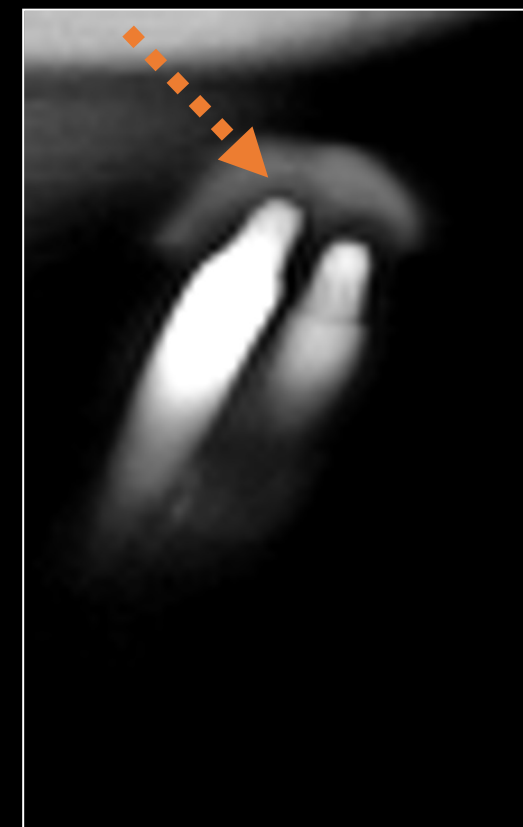
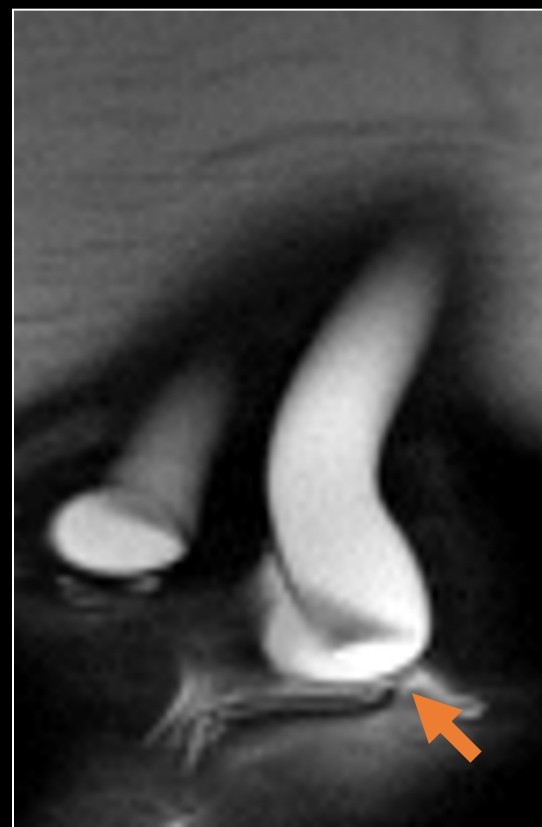
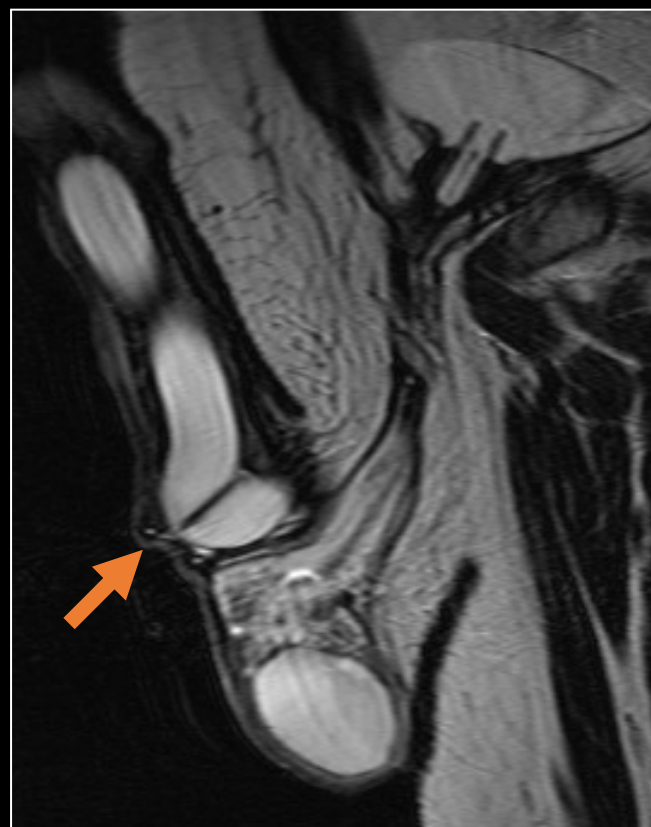
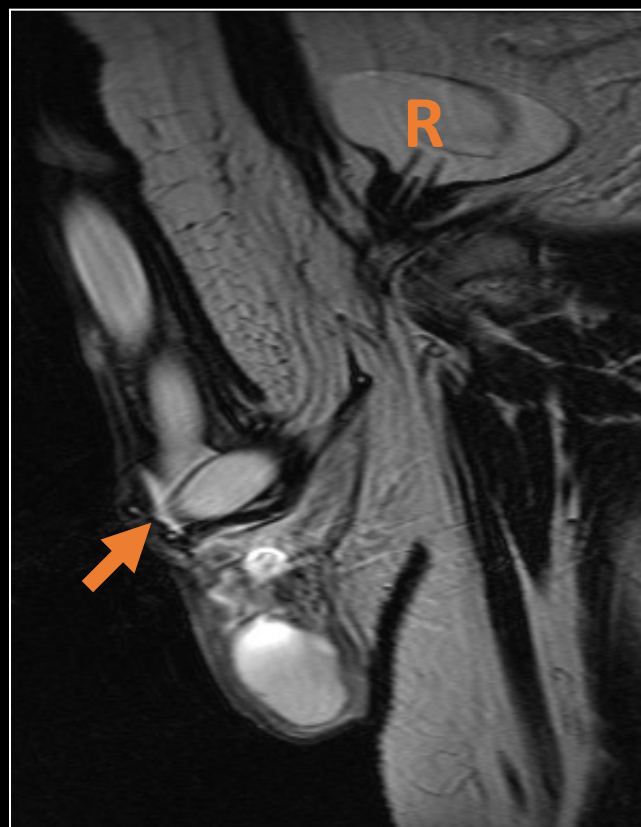


# IPP erosion and abnormal position



Detached left cavernosal rear extender (**arrows**). The rear extender is separated from the cylinder and completely reversed with the posterior component located anteriorly. Compare the right rear extender which is in normal position (**arrowhead**). Note some air within the left cylinder consistent with a system leak (**circle**).

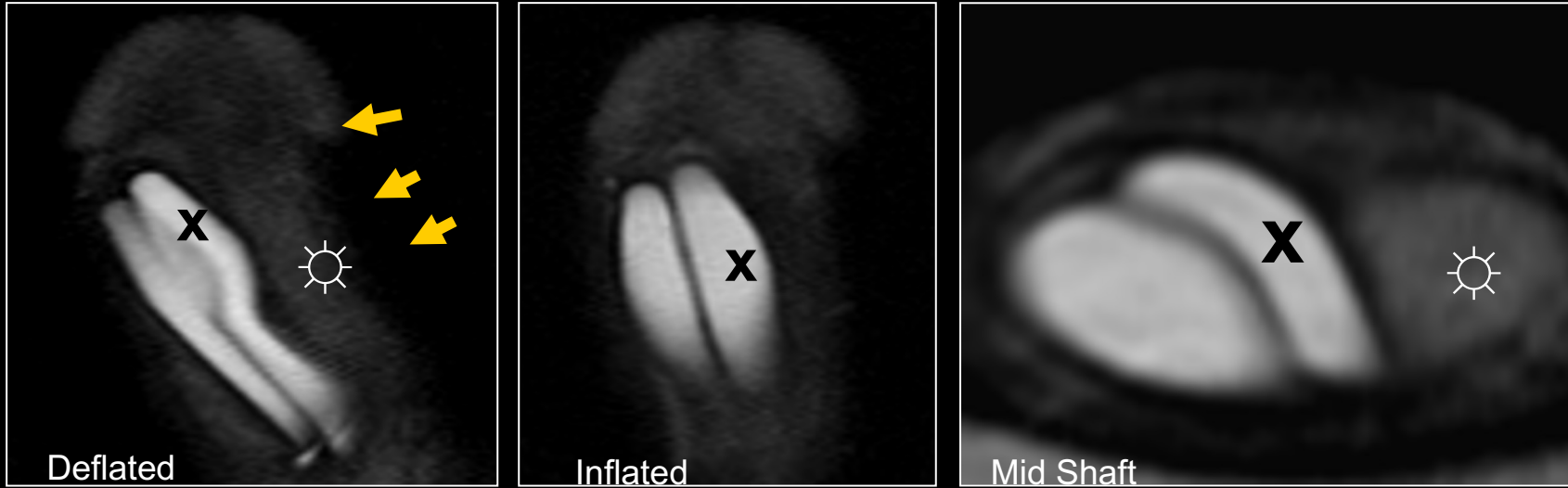
# IPP buckling



The left cylinder shortening, due to buckling (**arrow**), results in mild length discrepancy since the right cylinder (**dashed arrow**) extends further out towards the glans (**R** = reservoir)

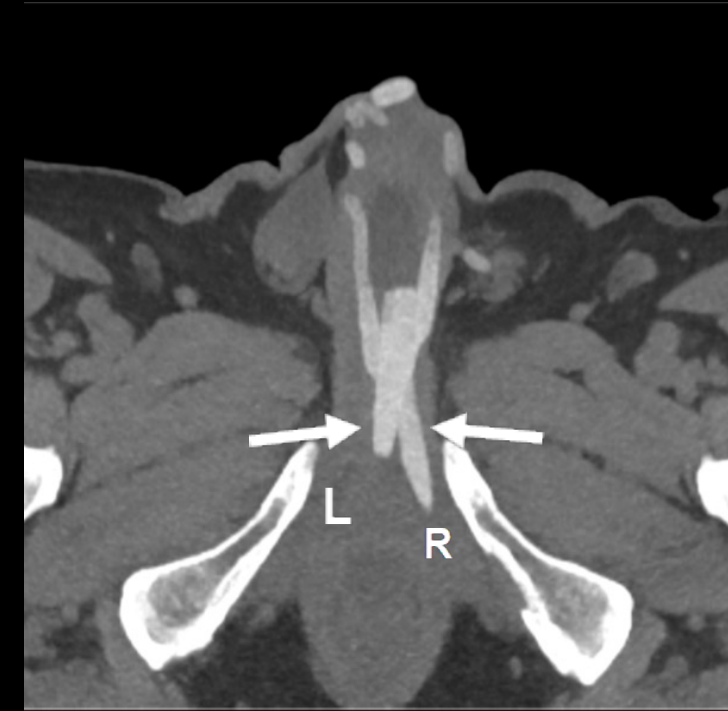

# IPP crossover



Adequate deflation and inflation of the cylinders, however left cylinder (X) crosses into the right CC into with empty distal left CC (☼). This results in curvature of the penile shaft and poor support of the left side of the glans (arrows)

May occur during placement as the **thin cavernosal septum can be disrupted during dilation** but if identified can be corrected intraoperatively.



CT demonstrating crossover of the proximal cavernosal components (arrows), with the right component (R) seated in the left base of the penis and the left component (L) seated just to the right of midline.



# Summary

---

- Because dedicated penile imaging examinations are not frequently performed, a case-based review of imaging for penile pain can help radiologists understand which imaging modality to use and how to interpret these examinations and improve communication with urologists.
- MRI provides greater soft tissue contrast for help identifying fractures, thrombus, fistulas and implants prosthesis, and contrast can be key for inflammatory processes.
- Imaging extent of Peyronie disease guides decision between medical and surgical treatment options.

# References and additional reading

---

- Abualruz AR, O'Malley R, Ponnatapura J, et al. MRI of common penile pathologies and penile prostheses. *Abdom Radiol (NY)* 2020;45(9):2825-2839.
- Acampora C, Borzelli A, Di Serafino M, et al. High-flow post-traumatic priapism: diagnostic and therapeutic workup. *J Ultrasound* 2021;24(4):539-545.
- Almeida JL, Felicio J, Martins FE. Surgical Planning and Strategies for Peyronie's Disease. *Sex Med Rev* 2021;9(3):478-487.
- Avery LL, Scheinfeld MH. Imaging of penile and scrotal emergencies. *Radiographics*. 2013 May;33(3):721-40.
- Bertolotto M, Campo I, Sachs C, et al. Sonography of the penis/erectile dysfunction. *Abdom Radiol (NY)* 2020;45(7):1973-1989.
- Di Serafino M, Acampora C, Iacobellis F, et al. Ultrasound of scrotal and penile emergency: how, why and when. *J Ultrasound*. 2021 Jun;24(2):211-226.
- Levine L, Rybak J, Corder C, and Farrel MR. Peyronie's disease plaque calcification—prevalence, time to identification, and development of a new grading classification. *J Sex Med* 2013;10:3121–3128.
- Levine LA, Larsen S. Diagnosis and Management of Peyronie Disease. In *Campbell-Walsh Urology*, 11th Edition. Elsevier, 2016.
- Nicola R, Carson N, Dogra VS. Imaging of traumatic injuries to the scrotum and penis. *AJR Am J Roentgenol*. 2014 Jun;202(6):W512-20.
- Pathak RA, Broderick GA. Color Doppler Duplex Ultrasound Parameters in Men Without Organic Erectile Dysfunction. *Urology* 2020;135:66-70.
- Pathak RA, Rawal B, Li Z, Broderick GA. Novel Evidence-Based Classification of Cavernous Venous Occlusive Disease. *J Urol* 2016;196(4):1223-1227.
- Steinkeler JA, Sun MRM. Imaging of Infections of the Urinary and Male Reproductive Tracts. *Semin Roentgenol*. 2017 Apr;52(2):83-89.
- Weyne E, Schillebeeckx C, Jamaer C, et al. Idiopathic Partial Thrombosis (IPT) of the Corpus Cavernosum: A Hypothesis-Generating Case Series and Review of the Literature. *J Sex Med*. 2015 Nov;12(11):2118-25.
- Wilson SK. Surgical techniques: modeling technique for penile curvature. *J Sex Med* 2007;4(1):231-234.